

# Maxillary Sinus Augmentation Using a Titanium Mesh: A Randomized Clinical Trial

Khalid Bahaa-Eldin<sup>1</sup>, Basma Mostafa<sup>1\*</sup>, Sherine Nasry<sup>1</sup>, Ahmed Reda<sup>2</sup>, Mona Shoeib<sup>2</sup>

<sup>1</sup>*Surgery and Oral Medicine Department, Oral and Dental Research Division, National Research Centre, Cairo, Egypt;* <sup>2</sup>*Oral Medicine, Periodontology and Diagnosis Department, Faculty of Oral and Dental Medicine, Cairo University, Cairo, Egypt*

## Abstract

**Citation:** Bahaa-Eldin K, Mostafa B, Nasry S, Reda A, Shoeib M. Maxillary Sinus Augmentation Using a Titanium Mesh: A Randomized Clinical Trial. Open Access Maced J Med Sci. 2017 Jun 15; 5(3):359-369. <https://doi.org/10.3889/oamjms.2017.083>

**Keywords:** Augmentation; graft; maxillary sinus; titanium mesh; bone.

**\*Correspondence:** Basma Mostafa. Surgery and Oral Medicine Department, Oral and Dental Research Division, National Research Centre, Egypt. E-mail: boshta@hotmail.com

Received: 18-Mar-2017; Revised: 08-Apr-2017; Accepted: 09-Apr-2017; Online first: 12-Jun-2017

**Copyright:** © 2017 Khalid Bahaa-Eldin, Basma Mostafa, Sherine Nasry, Ahmed Reda, Mona Shoeib. This is an open-access article distributed under the terms of the Creative Commons Attribution-NonCommercial 4.0 International License (CC BY-NC 4.0).

**Funding:** This research did not receive any financial support.

**Competing Interests:** The authors have declared that no competing interests exist.

**BACKGROUND:** Various attempts have been implemented using different materials and techniques to augment the maxillary sinus floor for prospect dental implant positioning.

**AIM:** This contemplate was conducted to assess the osteogenic capability of the maxillary sinus in a two-step sinus membrane elevation using titanium mesh to keep the formed space to place dental implants in atrophic ridges.

**MATERIALS AND METHODS:** Titanium micromesh was customized and positioned into the sinus on one side to preserve the elevated membrane in position. On the other side xenograft was applied. Instant and 6-months postoperative cone beam computed tomography (CBCT) was done to assess the gained bone height and density. Bone core biopsies were obtained during implant placement for histological and histomorphometric evaluation.

**RESULTS:** The average bone height values increased in both groups. Meanwhile the average bone density value was higher at the graft group than the titanium mesh group. Histological and histomorphometric evaluation presented the average bone volume of the newly formed bone in the graft group which is superior to that of the titanium mesh group.

**CONCLUSION:** The use of the titanium micromesh as a space-maintaining device after Schneiderian membrane elevation is a trustworthy technique to elevate the floor of the sinus without grafting.

## Introduction

Dental implants have been used widely in partially or completely restoring missing teeth. Maxillary sinus pneumatization and defective bone quality and quantity are amid the factors that limit maxillary ridge rehabilitation using dental implants [1]. Various adjunctive surgical techniques have been developed to improve the quality of bone and the surrounding soft tissues and conquer the bone volume deficiency for successful placement and support of dental implants [2].

Maxillary sinus augmentation has been first presented by Tatum meanwhile Boyne and James were the first to utilize autologous bone grafts with reported long-term follow-up [3]. Sinus augmentation is performed by grafting the surgically produced partition between the superiorly repositioned sinus membrane and the bony sinus floor with proper

materials [4]. Numerous grafting materials that can be implemented are autogenous bone, alloplastic and allogenic materials [5]. Autogenous bone is regarded the most superior material for sinus floor augmentation in terms of histological performance. However, donor area morbidity and graft volume loss are amid the major disadvantages of autogenous bone, which directed the majority of efforts towards using bone substitutes and new grafting techniques [6]. There after evolved the idea of maxillary sinus membrane lifting without the application of any bone grafts; which was first presented by Lundgren and co-authors [7].

During the past decade, several contemplates presented the cautious elevation of the Schneiderian membrane followed by concurrent placement of the root form implants to act as tent poles under the membrane [8-14]. Long-period studies using similar technique showed high implant survival rates with marginal bone resorption around the positioned

implants within the acceptable range [15-17].

Attempts were done at introducing space-making devices under the elevated maxillary sinus membrane when no implants could be concurrently placed. Recently, titanium mesh has received growing attention as many documented predictable and consistent results with the use of this material [18]. Many profits of the use of titanium mesh have been recommended. Titanium mesh provides superior space preservation, a basic prerequisite for any bone regeneration procedure. In addition, the pores within the titanium mesh are thought to play a significant role in maintaining and preserving blood supply to the grafted defect. However, the process of new bone formation using titanium mesh is not fully explained. In addition it has also been suggested that the use of titanium mesh could provoke the flap dehiscence and subsequent graft failure. The lateral window approach has been regarded as the classical technique for augmenting the maxillary sinus floor especially when the initial alveolar bone height does not insure primary stability of the implant. It can be done either in a single step with immediate implant placement or in two stages with delayed implant placement, depending on the available quantity and quality of remaining bone at the atrophic ridge site [19, 20].

Therefore the rationale of this study is to evaluate the osteogenic capability of the maxillary sinus in a two-step sinus membrane elevation using titanium mesh to maintain the created gap after membrane elevation without the use of any graft or space-filling material for future site preparation for the positioning of dental implants in severely atrophied posterior maxillary ridge.

## Materials and Methods

The study was a double blinded study using a split-mouth design. Four patients (2 females and 2 males), with a total of eight sinuses which were augmented for future implant placement. The age range of the patients was between 33-55 years with a mean of  $40.5 \pm 6.65$  years. All patients were recruited from the outpatient clinic of the Periodontology Department, Faculty of Oral and Dental Medicine, Cairo University and the outpatient dental clinic at the National Research Centre, Giza. The study protocol was approved by the Ethical Committee at the National Research Centre and an informed consent after all the study procedures were explained to each patient was obtained. The selected patients were systemically free with complete absence of any infection or pathosis in the bone or covering mucosa at the edentulous site or major bony septa as evident on the panoramic radiograph. The distance between the crest of the ridge and the floor of the sinus in

areas planned for future implantation had to be less than 5 mm with proper antro-posterior, transverse and vertical dimensions at centric occlusion. Good oral and periodontal health is also required in the selected patients. Patients who had previous surgery done in the maxillary sinus were excluded. Also pregnant females and smokers were not included. Each patient was interviewed in order to obtain a comprehensive history, including full medical and dental history.

Patients were assigned to one of the two treatment groups using computer generated randomization table (Research Randomizer computer software, version 4.0, Pennsylvania, USA) with a drop out ratio 10-15 %.

Allocation concealment was obtained using sealed coded opaque envelopes containing the treatment to the specific subject. The sealed envelope containing treatment assignment was opened at time of the surgery.

Four patients were selected indicated for bilateral external sinus elevation procedure, so that a total of 8 sinuses were enrolled in the present work. A study of a continuous response variable from matched pairs of study subjects with sample size calculation was planned. Prior data indicate that the difference in the response of matched patients was normally distributed with standard deviation (SD) 2.47. If the true difference in the mean response of matched patients is 0.2, we needed to study 8 sides to be able to reject the null hypothesis that this response difference was zero with probability (power) 0.09. The Type I error probability associated with this test of this null hypothesis was 0.05.

### *Preoperative procedures*

A comprehensive intraoral examination of the remaining teeth and soft tissue condition at the edentulous ridge was performed as well as evaluation of the inter-arch space, the width of the alveolar bone and the thickness of the covering tissue. Preoperative digital panoramic radiograph was done for each patient as a primary survey with a magnification 1:1.

For the selected patients, preoperative cone beam computed tomography (CBCT) scans were also performed while the patients were wearing a radiographic/surgical stent to precisely measure the bone height and density at the area considered for surgery and future implantation. Location of the exact mesio-distal dimension of the lateral-window osteotomy during surgery and the bone thickness was done in order to determine the amount of drilling to avoid perforation of the Schneiderian membrane.

An alginate impression was taken for the chosen patients, and then a diagnostic wax up was made. A maxillary partial denture was fabricated prior to the surgery, to point out accurately the proposed area that requires sinus elevation. This denture was

checked properly with the opposing teeth to check on the occlusion.

All patients received a single dose of IV antibiotic (ampicillin/sulbactam 1500 mg) in the form of Unasyn 1500 mg vial, Pfizer, USA) and another IV corticosteroids injection (Dexamethasone sodium phosphate 8 mg/2ml, Organium laboratories, UK) half an hour before the operation as prophylactic measures.

### **Surgical procedures**

The surgery was done under local infiltration anesthesia consisting of 2 % lidocaine hydrochloride and 1: 100000 epinephrine administrated in the buccal vestibule and the palatal mucosa opposite to the site of surgery. A lateral sinus floor elevation was performed according to Boyne and James [5] (Figures 1-3). After sinus elevation, maintenance of the newly created space was accomplished using a xenogenic bone grafting material for the control group or graft group (Group A) as seen in Figure 4 and a titanium (Ti) mesh for the intervention group or the Ti mesh group (Group B) as shown in Figure 5 without adding any bone filling material.

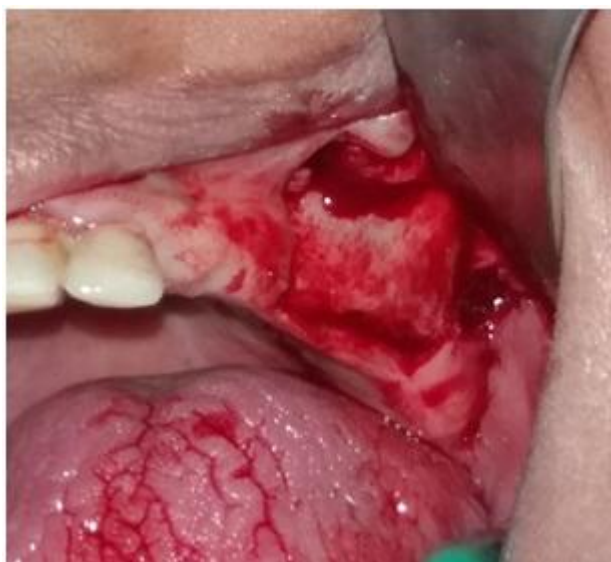

Figure 1: Mucoperiosteal flap reflection

The mucoperiosteal flap was performed using a mucoperiosteal elevator in the form of three lines in order to expose the lateral wall of the maxilla. It started from the crestal incision positioned slightly palatal to the crest of the ridge and then extended mesially and distally to facilitate the flap reflection. This was done to delineate the outline of the rectangular osteotomy and was guided by the radiographic surgical stent. Exact measurements were taken from the preoperative CBCT radiograph and then transferred to the bone to determine exactly the site of the surgery.

DASK (Dentium Advanced Sinus Kit, California, USA) drill #4 or #5 was used to prepare a lateral sinus window using light pressure (800-1200 rpm) and rotating strokes.

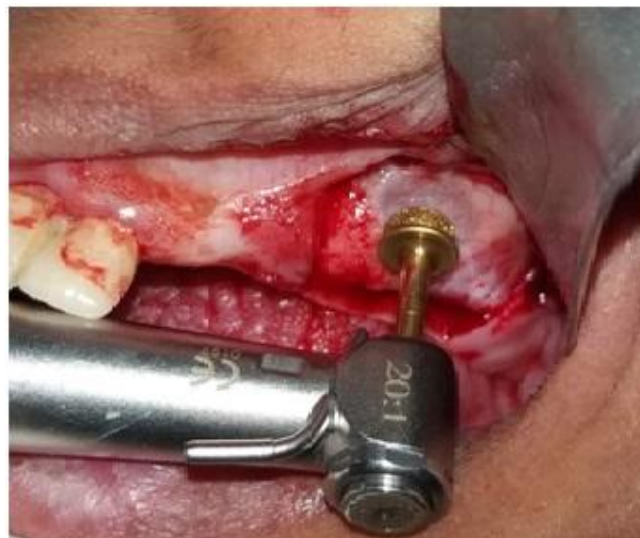

Figure 2: Drilling into the bone

The DASK drill is designed to minimize the risk of sinus membrane perforation by using cautious drilling to make a lateral window through the antrostomy (thin-out) approach on the bone while using copious irrigation with saline. Drilling was stopped once the sinus membrane appeared with its dull pinkish grey color. The membrane elevation started along the inferior border, then the medial surface of the lateral wall of the sinus around the boundaries of the window. The membrane was cautiously elevated from the lateral wall and the floor of the sinus cavity until the upper border of the osteotomy and lifted up to its new level.

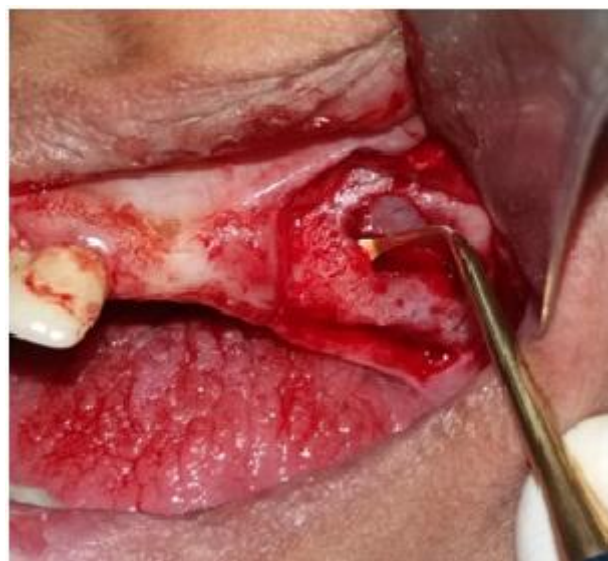

Figure 3: Maxillary sinus membrane elevation

The inward reflection of the osteotomy and

the elevated membrane resulted in an empty space with the wall of the sinus as its medial border and the antral membrane, while the upper side with the elevated lateral wall and antral membrane, and inferiorly bordered by the bony floor of the sinus. Before moving to the next step, the integrity of the sinus membrane was ensured using the Valsalva maneuver, which is performed by pinching the patient's nose, thus forcing a moderate exhalation, where the sinus inflates and deflates thus ensuring no perforations in its walls [21].

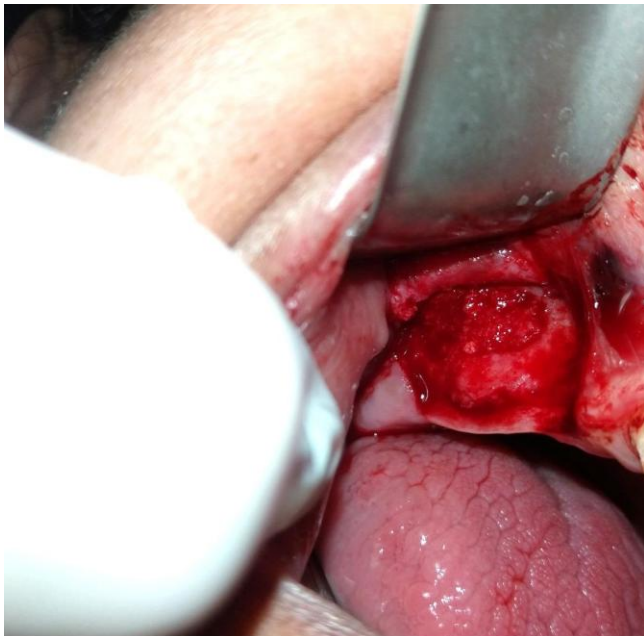


Figure 4: Bone graft filling the created cavity beneath the elevated sinus membrane

For the control group or graft group (Group A), a collagen membrane (Bio-Gide<sup>®</sup>, Geistlich Pharma, North America Inc) is inserted beneath the sinus membrane to protect it from the particles of the bone graft, then the created space is filled with a xenogenic bone graft (Tutobone<sup>®</sup>, RTI, Biologics, Germany). The osteotomy is then covered with a collagen membrane and the flap was readapted and sutured in its original position using a 3-0 black silk (Assut<sup>®</sup>, Switzerland) in an interrupted matter.

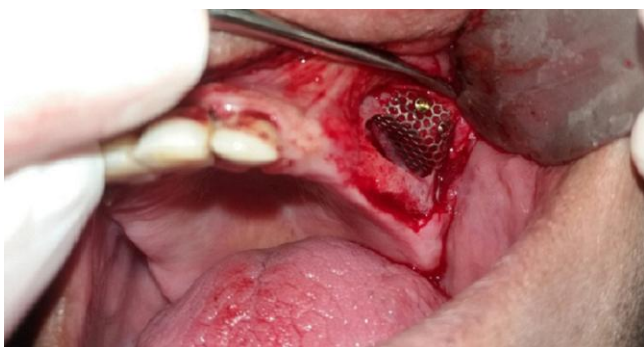


Figure 5: Fixation of the titanium mesh to the lateral wall of the sinus with micro-screws

For the intervention group or Ti mesh group (Group B), the width of the osteotomy was measured and a foil template was trimmed to fit exactly into the created space in an L-shape figure so that one side was resting on the lateral wall of the bone and the other side pushed inside the cavity supporting the membrane at its new level. A 0.1 mm thickness micro titanium mesh (Leibinger, Stryker Co., Geneva, Switzerland) was then cut and trimmed the same size as the template, and its sharp ends were smoothed to avoid tearing the sinus membrane. The titanium mesh was tailored in an L-shape so that the long arm is inserted inside the sinus cavity to support the Schneiderian membrane at its new level and the short arm is fixed to the lateral sinus wall with two micro screws (1.5 mm) above the site of the osteotomy. The osteotomy was then covered with a collagen membrane and the flap was readapted and sutured in its original position using also the 3-0 silk suture in an interrupted pattern.

### Postoperative instructions

Patients were instructed to apply ice packs for 10 minutes every 30 minutes for the first 24 hours. Meticulous oral hygiene measures were pertained, including: tooth brushing using soft brush carefully and chlorhexidine gluconate 0.1 % mouthwash (every 8 hours for two weeks). Avoidance of any negative or positive pressure like blowing the nose, drinking with a straw or even spitting hardly, for the first 24 hours were explained to the patients. Medical regimen included: a single dose of long acting corticosteroids: Methylprednisolone acetate 80 mg/ml I.M. immediately postoperative. An anti-inflammatory analgesic: Ketolactromethamine 30 mg/amp/2ml I.M. injection every 12 hours for the first 24 hours. Oral antibiotics: Ampicillin/sulbactam 375 mg tablets (every 8 hours for 10 days) + Clindamycin 150 mg capsules (every 6 hours for 4 days). Nasal decongestants: Oxymetazoline HCl 0.25% nasal drops (every 8 hours for 7 days). Systemic decongestants: Pseudoephedrine HCl 60 mg + Triprolidin HCl 2.5 mg tablets (every 8 hours for 7 days). Chlorohexidine Gluconate 0.1 % mouthwash (every 8 hours for two weeks) was prescribed. Sutures were removed after 7-10 days following the surgery.

### Clinical assessment

Regular clinical assessment was done for the patients after 48 hours, 1 week, 2 weeks, 1 month and then monthly until 6 months postoperatively evaluating the wound for signs of hematoma, bleeding, infection or even membrane exposure. The patients were examined also for signs and symptoms of sinusitis. Each patient was evaluated immediately after the surgery, 3 and 6 months post-operatively for the following: discomfort, tenderness and pain.

### Radiographic assessment

Radiographic follow up was done using CBCT preoperative and immediately postoperative as shown in Figure 6 and 6 months postoperatively as presented in Figure 7 and 8 to evaluate the formation of new bone. The patients submitted to this study were evaluated using Next Generation Scanora 3D CBCT scanner (Soredex, Tuusula, Finland). Images were taken prior to surgery, immediately postoperative and 6 months postoperatively. After acquisition, data were exported and transferred in a special format to be secondarily re-evaluated for height and density measurements, where dental software (version 5.3; Anatomage, San Jose, CA, USA) was used for that purpose. The software was used to determine the pre- and post-operative bone height after bone grafting and titanium mesh application as well. Height was measured in mm.

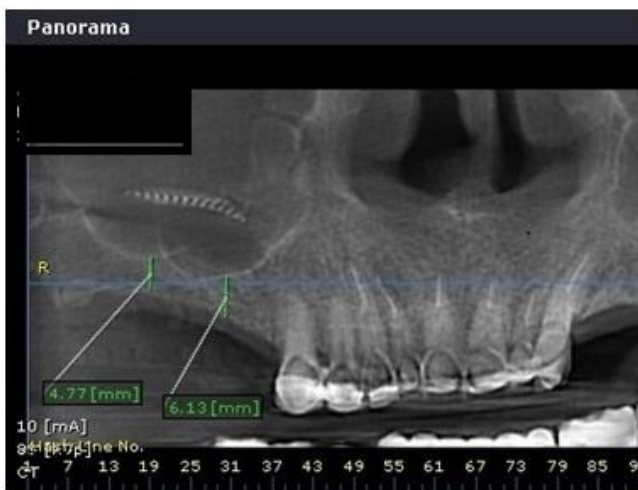

Figure 6: Reformatted panoramic view from CBCT with the exact bone height of the native bone immediately post operative titanium mesh fixation

The density of bone was measured in Hounsfield Units (Hu) at the graft site and the area inferior to the titanium mesh application were evaluated in reference to the native bone density in the alveolar ridge. Series of steps were followed to guarantee the standardization of measurements for both bone graft and titanium mesh position. At the software, section module was chosen; which presented the data in the axial, coronal and sagittal views.

The measurements were oriented in a certain position to ensure standardization as the sagittal line was made parallel to the alveolar ridge; hence, coronal line was automatically obtained in the buccopalatal orientation. At the coronal view, the mesial end of the bone graft was determined, and then the height of graft material and alveolar bone as well, were taken, and then, at each slice till the distal end of the graft material posteriorly same measurements were taken. The slice thickness was set at 0.25 mm in thickness and 1 mm interval between each slice. The

mean height of the bone graft was calculated, and the mean height of the alveolar ridge as well. For titanium mesh side, same steps were repeated with additional orientation step, where the axial line was made parallel to the mesh to ensure recording of the true vertical height inferior to the mesh at the coronal view.

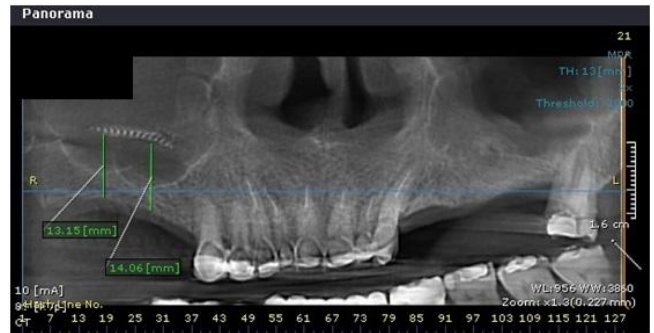

Figure 7: Reformatted panoramic view from CBCT for the same patient as in figure 6 with bone height gain 6 months post operative titanium mesh fixation

For Density measurements, the same steps used for height measurements were employed, where density readings were recorded as gray scale values at the same area measured for height. The same protocol was followed at each scan of every patient under the umbrella of the study periods. The steps of reconstructing the images were followed meticulously to ensure standardization of the views. The data were pooled on a data collection form and transferred later to an Excel (Microsoft, Palo Alto, CA, USA) spread sheet for analysis.

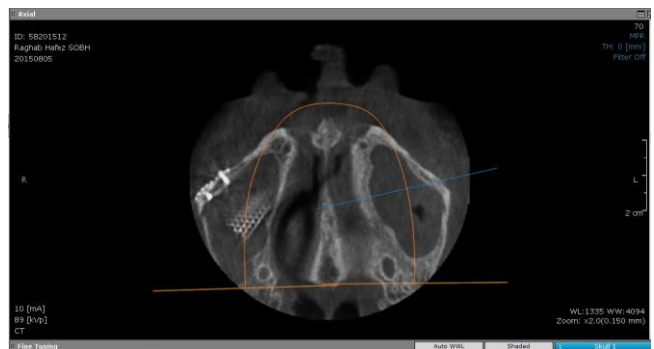


Figure 8: Axial view of CBCT six months postoperative showing titanium mesh in place with evidence of bone formation

### Histological Assessment

At the time of implant placement, core biopsies were retrieved, guided by the same radiographic-surgical stent used in the surgical procedures. The specimens obtained were immediately fixed in 10% buffered formalin for 1 week, then decalcified and processed according to a standardized protocol of Ethylene diamine tetra acetic acid (EDTA) formic acid combination. Then, specimens were embedded longitudinally into paraffin blocks and oriented in a standardized way for labeling

and differentiating the newly formed bone from the native bone end. Blocks were cut into longitudinal 5 mm-thick sections using a manual rotary microtome (RM 2135 microtome, Leica, Heidelberger Straße, Nussloch, Germany) and stained with Mayer's hematoxylin and eosin stain (H&E) and Masson Trichrome stain for histological and histomorphometric analysis.

### **Histomorphometric Analysis**

All the stained sections were examined with an Olympus CX20 (Olympus, Shinjuku-ku, Tokyo, Japan) microscope attached to a camera and a computer. For each of the native and newly formed bone specimens, the most representative five fields per specimen were captured using magnification (x100). Images of the slides were taken and saved as figure files; the image analysis was done with an image analyzer (Leica Qwin 500, LEICA Imaging Systems Ltd, Cambridge, England) computer system using the Image J software (v. 1.45e, National Institutes of Health, Bethesda, MD, USA) at the Pathology Department, National Research Centre, Cairo. The bone volume (bone area fraction) was measured for each image. For each sinus, the mean bone volumes of the native and newly formed bone were calculated for data analysis. Area fraction ( $\mu\text{m}^2$ ) of native and newly formed bone specimens were measured in five random fields per group and data obtained as mean area and standard error.

### **Statistical Analysis**

The mean  $\pm$  standard deviation (SD) values were calculated and presented for each group. Data showed parametric (normal) distribution. Paired-wise sample t-test was used to compare between related samples while independent-sample t-test was used to compare between unrelated samples. The significance level was set at  $p \leq 0.05$ . Statistical analysis was done using IBM<sup>®</sup> SPSS<sup>®</sup> Statistics Version 20 for Windows (SPSS Inc., Chicago, IL, USA).

## **Results**

The current contemplate was carried out on a total of 4 patients with 8 sides indicated for open sinus elevation surgery for future implant placement using the split mouth study design. Patients were randomly allocated into two groups. Their ages ranged from 35 to 55 years old with mean of ( $40.5 \pm 6.65$ ) years. The study included 4 males and 4 females. (Group A) the control or graft group which consisted of 4 sides indicated for external sinus elevation surgeries with

xenogenic bone graft augmentation. (Group B) the intervention or Ti mesh group consisted of the other 4 sides indicated for external sinus elevation surgeries using the titanium mesh for space-maintenance. All the height and density measurements were taken from the CBCT with special software preoperative, immediately postoperative and after 6 months.

### **Clinical results**

Wound healing was normal in all patients and the post-operative follow up period went uneventful without any signs of infection, suppuration, mucositis, abnormal bleeding, significant hematoma or flap dehiscence. Pain and minor swelling of gingival mucosa was noted in all patients that were completely resolved by the fifth day post-operatively. The membrane rise and mesh fixation procedures were done with no sinus membrane tears. After the second step surgery, a whole number of 14 implants were positioned, with primary steadiness gained in all the operated sinuses.

### **Radiographic results**

The postoperative CBCT showed opacifications below and surrounding the titanium mesh obvious in both the cross-sectional and panoramic views as seen in Figure 7 and axial view in Figure 8, which indicates the formation of a blood clot inside the formed space.

Six months postoperatively the CBCT showed substantial amounts of radio-opacities indicating new bone formation. In various cuts the bone did not plug the whole volume below the mesh, forming voids. The line of separation between the newly formed bone and the native bone could be recognized in nearly all the examined views.

### **Bone height results (in mm)**

The difference between pre and postoperative bone height in both control and intervention groups was statistically significant ( $p = 0.005$ ). For group (A) a statistically significant difference ( $p = 0.001$ ) was found between preoperative and postoperative bone height showing a mean bone height of  $3.39 \pm 0.89$  preoperatively and a mean bone height of  $12.58 \pm 2.01$  postoperatively. In group (B) the mean bone height was  $3.53 \pm 1.02$  preoperatively and  $11.46 \pm 2.78$  postoperatively. Although the postoperative bone height of the control group was higher than the intervention group, no statistically significant difference was seen between both groups ( $p = 0.54$ ), where results of the mean bone heights were  $12.58 \pm 2.01$  and  $11.46 \pm 2.78$  in the control and intervention groups respectively as seen in Table 1. Calculating the percentage of change revealed that the amount of bone height gain in the control group (73.05 %) was

more than the intervention group (69.20 %).

**Table (1): The mean  $\pm$  SD of bone height values (in mm) within each group pre and post-treatment**

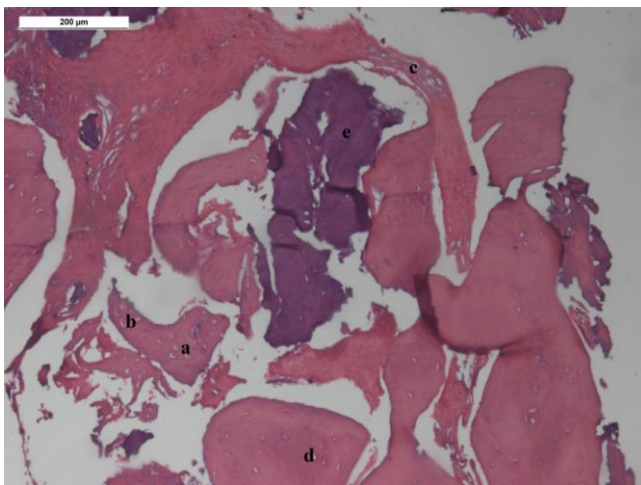
Time Periods	Groups	
	Control group	Intervention group
Pre	3.39 $\pm$ 0.89	3.53 $\pm$ 1.02
Post	12.58 $\pm$ 2.01	11.46 $\pm$ 2.78
p-value	0.001*	0.005*

### Bone density results (in Hu)

There was a statistically significant difference between the native and postoperative mean bone densities in both control and intervention groups ( $p = 0.03, 0.04$ ) respectively. The mean bone density of native bone before titanium application was  $265.00 \pm 14.14$  and following titanium application the density at the site reached  $182.00 \pm 37.31$ , while the mean bone density of native bone before bone graft application was  $345.25 \pm 51.86$  and reached  $246.75 \pm 43.29$  at the site of bone graft insertion. There was no statistically significant difference in bone density between (Post-Titanium) ( $182.00 \pm 37.31$ ) group and (Post-Bone Graft) ( $246.75 \pm 43.29$ ) group where ( $p = 0.06$ ). The amount of bone density gain in relation to the native bone density values in group (A) was 71.5% and in group (B) it was 68.7%.

### Histological results

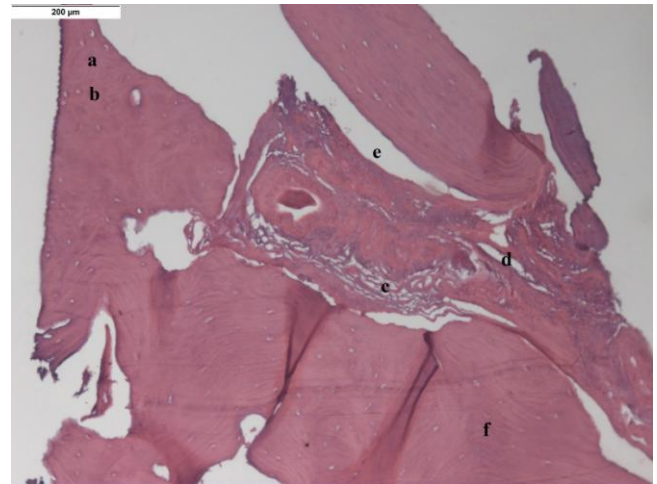
Clinical explanation of the obtained core biopsies showed that the color of the newly formed bone was coral pink, as compared with the white color of the native bone. The length of the cores was nearly of the same length as expected from the 6 months postoperative CBCT.



**Figure 9:** Photomicrograph 6 months postoperative in the graft group showing the native bone (a) with mature trabecular bone with clearly seen lamellae and lacunae of osteocytes (b), few granulation tissue (c), newly formed bone (d) and remnants of the grafting material (e) (H&E x 100)

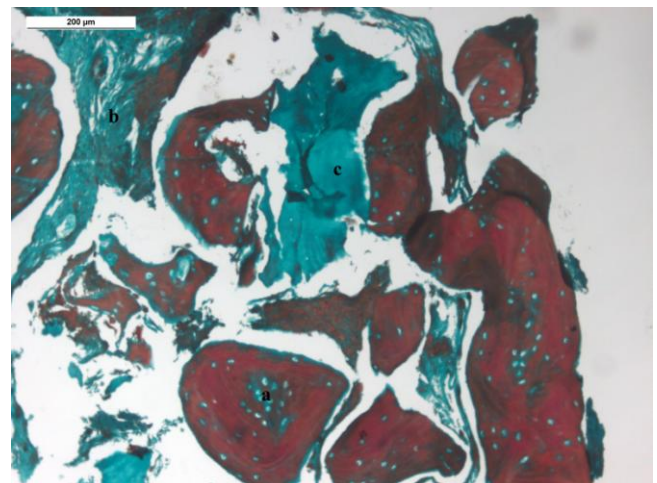
In the H&E (Figures 9 & 10) and Masson trichrome (Figures 11 & 12) sections histological investigations of the grafted cases showed the native

bone with occurrence of mature trabecular bone with evidently seen lamellae; small amounts of inflammatory cells infiltration were detected in the marrow cavities. Moderate amounts of osteoblasts and small amount of osteoclasts were presented with no evidence of the completely resorbed grafting material. The newly formed bone was generally composed of interconnecting rods of woven bone presenting oriented collagen fibers interspersed in a backdrop of extracellular matrix rich in newly formed blood vessels or angiogenesis and newly created collagen fibrils.



**Figure 10:** Photomicrograph 6 months postoperative in the Ti mesh group showing the native bone (a) with mature trabeculae with clearly seen lamellae and lacunae of osteocytes (b), granulation tissue (c), angiogenesis (d), osteoblastic rimming (e), newly formed bone (f) (H&E x 100)

Osteocytes were unevenly oriented within the bony matrix. Osteoblastic rimming could be seen delineating the marrow spaces. Small to moderate areas of trabecular bone with clearly seen lamellae adjoining narrow marrow spaces were seen, with few inflammatory cells. Immature formed bone was also observed.



**Figure 11:** Photomicrograph 6 months postoperative in the graft group showing the newly formed bone with lacunae of osteocytes (a), granulation tissue and remnants of the grafting material (c) (Masson Trichrome stain x 100)

In the Ti mesh cases, the native bone showed mature trabecular bone, evidently seen lamellae, lacunae of osteocytes and newly formed bone.

### Histomorphometric analysis results

The bone area of the native bone of grafted cases ranged from 26.68 % to 41.85% with a mean value of  $36.7 \pm 5.36$  %, meanwhile the bone area of the newly formed bone ranged from 8.11% to 26.96% with an average value of  $13.59 \pm 3.53$ %.

In the Ti mesh cases the bone area of the native bone ranged from 28.38% to 44.2% with a mean value of  $34.81 \pm 2.51$ %, meanwhile the bone area of the newly formed bone ranged from 34.81% to 8.31% with a mean value of  $5.81 \pm 0.73$ %.

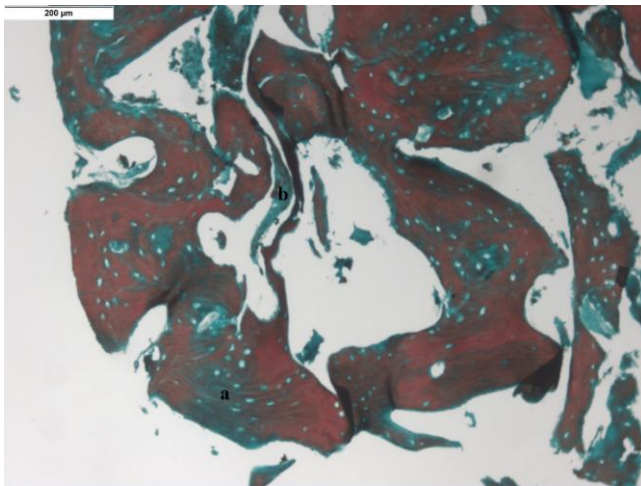


Figure 12: Photomicrograph 6 months postoperative in the Ti mesh group showing the newly formed bone with lacunae of osteocytes (a) and granulation tissue (Masson Trichrome stain x 100)

No significant difference (NS) of native bone results was recorded in Ti mesh cases with  $p < 0.05$  as compared with grafted cases. Significant (S) difference of newly formed bone results was seen in Ti mesh cases with  $p < 0.05$  as compared with the new bone in the grafted cases which was higher in this group as recorded in Table 2.

Table 2: The mean bone volume % (Bone Area Fraction) for each sinus

Case	Type of bone	Area	Area Fraction	Area%
Grafted	Native	4369.11	0.36	$36.77 \pm 5.36$
	Newly Formed	1299.33	0.13	$13.59 \pm 3.53$
Ti	Native	4136.16	0.34	$34.81 \pm 2.51$ (NS)
	Newly Formed	691.12	0.058	$5.81 \pm 0.73$ (S)

NS: Non significant; S: Significant.

## Discussion

Several studies have concluded that sinus membrane elevation accompanied by simultaneous

implant placement resulted in new bone formation without placement of any grafting material. However it is not yet clear how bone is formed in such non-grafted sinuses. Previous research has highlighted the osteogenic potential of cells isolated and cultured from the lining of the maxillary sinus and the ability of these cells to form bone in ectopic conditions [22, 23]. On the other hand it was debated that the walls and septa of the sinus are responsible for new bone formation similar to the mechanism of bone formation in extraction sockets after clot formation [24, 25].

Since the height or quality of the residual alveolar crest may not always be enough to provide the initial stability for simultaneous implant placement, studies have attempted the insertion of a space maintaining device after the process of sinus membrane elevation to evade non-supported sinus membrane crumple to maintain the gained space [16].

Thus the aim of the current contemplate was to assess the capability of a micro titanium mesh, acting as a space maintaining device after Schneiderian membrane elevation, to enhance new bone formation in the sinus without the need to use of any grafting material.

The titanium mesh chosen as a space maintaining device in this study is characterized by its excellent biocompatibility. It is easily shaped and adapted on the bone surface, and rigid enough to maintain the sinus at the new level. The holes of the mesh allow direct contact between the blood clot in the newly formed space and the Schneiderian membrane with its osteogenic property, and its 0.1 mm thickness preserves all of the formed space allowing the placement of the longest possible implant [26].

The xenograft used as a positive control in the present study is an ideal scaffold for osseointegration and can resist resorption caused by increased pneumatization of the sinus as a result of increased sinus pressure [27, 28].

The shape of the osteotomy in this study was chosen to be rectangular in shape with rounded corners to easily accommodate the titanium mesh during insertion and fixation [29]. A study of the arterial architecture of the maxillary sinus' area explained that the vascularization of the grafting material used in sinus elevation procedures occurs through the endosseous and extraosseous arterial anastomosis. In the present study, the osteotomies were large enough to make sure that the titanium mesh covers all the area planned for the bone formation and future implant placement [30].

The issue of the real need to cover the osteotomy window with a collagen membrane or not is still arguable. Some authors preferred to cover up the osteotomy to rule out non-osteogenic connective tissue infiltration and avoid the escape of the graft particles, while others say there's no need for the



collagen membrane coverage. In the present study the lateral window was enclosed with a membrane to avoid the infiltration of non osteogenic connective tissue into the cavity [31].

Tawil and Mawla noticed a lack of cortication of the graft surface together with enclavation through the sinus window, which was due to the fibrogenic nature of the periosteum once it has been elevated from the bone surface [32]. In the present study minor enclavations were seen in most of the cases (radiographically and histologically); however it neither affected the bone density nor the width of the future implant placement sites.

The lateral window approach for maxillary sinus elevation used here is a predictable and simple technique and offers good and clear access to the Schneiderian membrane [13]. It was reported that the lateral approach for sinus elevation showed more bone formation than the bone added osteotome sinus floor elevation technique [33].

Results of the present study demonstrated a postoperative increase in bone height and bone density in both graft and titanium mesh groups which was bigger in the graft group but with no statistically significant difference.

Although the xenograft used here acted as a good scaffold for osseinduction it did not resorb completely as evident histologically. The xenograft was shown to undergo slow or no resorption for up to 6 years, hence failing to remodel and adapt to the surrounding bone [34].

Both radiographic and histological results demonstrated the effectiveness of the osteoinductive allograft in forming new bone which is consistent with previous studies using similar graft materials, demonstrating the osteoinductive ability of xenograft when used as the sole grafting material in maxillary sinus augmentation [35, 36]. Histologically xenograft was shown to form new trabecular bone and gain satisfactory results in terms of bone height that prove that it is a suitable augmenting material for atrophic maxillary rehabilitation [37]. Another research demonstrated that long-term outcome after sinus augmentation were in favor of xenograft when compared with autogenous graft where only 4.2 % of 47 cases showed 50 % reduction of augmented height in the xenograft group compared to the 8.7 % cases in the autogenous group [38].

On the other hand, the titanium mesh proved to maintain the space below the Schneiderian membrane as demonstrated by the 6 months postoperative CBCT. Previous studies on localized alveolar reconstruction for guided bone regeneration purposes recommended the use of titanium mesh to maintain the space that will be filled with materials like bone morphogenetic proteins, platelet rich plasma or platelet rich fibrin [39].

The same idea of space maintenance

beneath the sinus membrane without the placement of any grafting material was implemented in a former study using a bioresorbable tenting device with simultaneous implant placement. The results were however quite disappointing revealing new bone formation only at the implant surface. The authors attributed these results to several factors which included lack of stabilization of the device inside the sinus cavity, disturbed healing process by the rigid material of the device, making its reshaping difficult, or extensive healing that might have caused small initial perforations to be widened. Moreover, the surface of the used device being smooth and broad in width might have increased the contact area with the Schneiderian membrane, thus hindering its osteogenic properties [16].

Thor et al studied the amount of bone gain by the tenting technique revealing a mean bone height gain of 6.51 mm with an average residual bone height of 5.5 mm [14]. Leblebicioglu reported less gain in bone height than the present study with an average bone gain of 3-4 mm. In the current study the bone height was nearly doubled 6 months after the operation. The tenting technique in Leblebicioglu's study [40] resulted in bone formation around the apex only while in the current study both the reformatted cross-sections and panoramic views CBCT showed bone formation over the area beneath the titanium mesh.

Results in the present study demonstrated that the bone gain in the titanium mesh group was still not complete as it did not reach the titanium mesh in some areas as shown on the CBCT, implying that more time is needed for the bone to fill all over the created chamber. However the x-rays demonstrated that in the areas for planned future implant placement the bone reached up to 11 or 12 mm which is enough for implant placement with proper primary stability.

The present results are in accordance with previous case series study results where the elevated sinus membrane was maintained by fixing a titanium plate to the lateral wall of the sinus, where only 40.2 % of the space below the plate was maintained after 6 months [2]. In this case series study 6 months postoperative CBCT demonstrated a small gap between the titanium mesh and the newly formed bone. In this contemplate the average residual ridge height reached  $9.63 \pm 1.47$  mm after 6 months which is comparable to the results of the present study demonstrating  $11.46 \pm 2.78$  mm mean bone height 6 months postoperatively.

Bone formation inside the sinus cavity requires the migration and differentiation of osteogenic cells into osteoblasts, where they start to synthesize and deposit collagenous matrix for mineralization. The bone marrow is the main source of such cells and it is thought that the mesenchymal stem cells (MSCs) migrate from the bone marrow into the blood filled sinus cavity using the fibrin network as

a scaffold. Lifting the periosteum initiates bone resorption, exposure of the bone marrow and access of stem cells to the sinus cavity as mentioned in a previous study [9].

Kim et al carried out an in vitro study where it was observed that the source of bone forming cells is the periosteum of the lifted sinus membrane that contributed mainly in the process of bone formation. The presence of MSCs with osteogenic properties in the maxillary sinus membrane was also confirmed. Another source of the osteogenic cells might be from the periosteum of the osteogenic layer covering the lateral window. The titanium mesh surface texture might have a certain role in bone formation as it stimulates thrombin formation on the surface of titanium and together they both activate stimulation and inhibition of the apoptotic process of osteoblasts [29].

In conclusion, the titanium mesh can be used as a space maintaining device to support the Schneiderian membrane without using any grafting material. Future studies using larger sample size with longer follow up intervals are recommended.

## References

- Papadogeorgakis N, Prokopidi ME, Kourtis S. The use of titanium mesh in sinus augmentation. *Implant Dent*. 2010;19(2):109-14. <https://doi.org/10.1097/ID.0b013e3181d46a0c> PMID:20386213
- Atef M, Hakam MM, ElFaramawey MI, Abou-EIFetouh A, Ekram M. Nongrafted Sinus Floor Elevation with a Space-Maintaining Titanium Mesh: Case-Series Study on Four Patients. *Clinical implant dentistry and related research*. 2014;16(6):893-903. <https://doi.org/10.1111/cid.12064> PMID:23551586
- Boyne PJ, James RA. Grafting of the maxillary sinus floor with autogenous marrow and bone. *Journal of oral surgery (American Dental Association)*. 1980; 38: 613–616. PMID:6993637
- Corinaldesi G, Pieri F, Marchetti C, et al. Histologic and histomorphometric evaluation of alveolar ridge augmentation using bone grafts and titanium micromesh in humans. *J Periodontol*. 2007; 78:1477-1484. <https://doi.org/10.1902/jop.2007.070001> PMID:17668966
- Longoni S, Sartori M, Apruzzese D, et al. Preliminary clinical and histologic evaluation of a bilateral 3-dimensional reconstruction in an atrophic mandible: A case report. *Int J Oral Maxillofac Implants*. 2007; 22:478-483. PMID:17622016
- Maiorana C, Santoro F, Rabagliati M, Salina S. Evaluation of the use of iliac cancellous bone and anorganic bovine bone in the reconstruction of the atrophic maxilla with titanium mesh: a clinical and histologic investigation. *Int J Oral Maxillofac Implants*. 2001; 16: 427–432. PMID:11432663
- Lundgren S, Andersson S, Gualini F, Sennerby L. Bone reformation with sinus membrane elevation: a new surgical technique for maxillary sinus floor augmentation. *Clin Implant Dent Relat Res*. 2004; 6:165–173. <https://doi.org/10.1111/j.1708-8208.2004.tb00224.x> PMID:15726851
- Palma VC, Magro-Filho O, de Oliveria JA, Lundgren S, Salata LA, Sennerby L. Bone reformation and implant integration following maxillary sinus membrane elevation: an experimental study in primates. *Clin Implant Dent Relat Res*. 2006; 8:11–24. <https://doi.org/10.2310/j.6480.2005.00026.x> PMID:16681489
- Sul S-H, Choi B-H, Li J, Jeong S-M, Xuan F. Effects of sinus membrane elevation on bone formation around implants placed in the maxillary sinus cavity: an experimental study. *Oral Surg Oral Med Oral Pathol Oral Radiol Endod*. 2008; 105:684–687. <https://doi.org/10.1016/j.tripleo.2007.09.024> PMID:18299220
- Xu H, Shimizu Y, Ooya K. Histomorphometric study of the stability of newly formed bone after elevation of the floor of the maxillary sinus. *Br J Oral Maxillofac Surg*. 2005; 43:493–499. <https://doi.org/10.1016/j.bjoms.2005.02.001> PMID:15908076
- Kim HR, Choi BH, Xuan F, Jeong SM. The use of autologous venous blood for maxillary sinus floor augmentation in conjunction with sinus membrane elevation: an experimental study. *Clin Oral Implant Res*. 2010; 21:346–349. <https://doi.org/10.1111/j.1600-0501.2009.01855.x> PMID:20443793
- Hatano N, Sennerby L, Lundgren S. Maxillary sinus augmentation using sinus membrane elevation and peripheral venous blood for implant-supported rehabilitation of the trophic posterior maxilla. *Clin Implant Dent Relat Res*. 2007; 9:150–155. <https://doi.org/10.1111/j.1708-8208.2007.00043.x> PMID:17716259
- Chen TW, Chang HS, Leung KM, Lai YL, Kao SY. Implant placement immediately after the lateral approach of the trap door window procedure to create a maxillary sinus lift without bone grafting: a 2-year retrospective evaluation of 47 implants in 33 patients. *J Oral Maxillofac Surg*. 2007; 65: 2324–2328. <https://doi.org/10.1016/j.joms.2007.06.649> PMID:17954333
- Thor A, Sennerby L, Hirsch JM, Rasmusson L. Bone formation at the maxillary sinus floor following simultaneous elevation of the mucosal lining and implant installation without graft material: an evaluation of 20 patients treated with 44 Astra Tech implants. *J Oral Maxillofac Surg*. 2007; 65:64–72. <https://doi.org/10.1016/j.joms.2006.10.047> PMID:17586351
- Ellegaard B, Baelum V, Kølsen-Petersen J. Non-grafted sinus implants in periodontally compromised patients: a time-to event analysis. *Clin Oral Implant Res* 2006; 17:156–164. <https://doi.org/10.1111/j.1600-0501.2005.01220.x> PMID:16584411
- Cricchio G, Sennerby L, Lundgren S. Sinus bone formation and implant survival after sinus membrane elevation and implant placement: a 1- to 6-year follow-up study. *Clin Oral Implant Res*. 2011; 22:1200–1212. <https://doi.org/10.1111/j.1600-0501.2010.02096.x> PMID:21906186
- Lin IC, Gonzalez AM, Chang HJ, Kao SY, Chen TW. A 5-year follow-up of 80 implants in 44 patients placed immediately after the lateral trap-door window procedure to accomplish maxillary sinus elevation without bone grafting. *Int J Oral Maxillofac Implants*. 2011; 26:1079–1086. PMID:22010092
- Her S, Kang T, Fien MJ. Titanium mesh as an alternative to a membrane for ridge augmentation. *J Oral Maxillofac Surg*. 2012;70(4):803-10. <https://doi.org/10.1016/j.joms.2011.11.017> PMID:22285340
- Schweikert M, Botticelli D, De Oliveira JA, Scala A, Salata LA, Lang NP. Use of a titanium device in lateral sinus floor elevation: an experimental study in monkeys. *Clin Oral Implant Res*. 2012; 23:100–105. <https://doi.org/10.1111/j.1600-0501.2011.02200.x> PMID:21518009
- Johansson L-Å, Isaksson S, Adolfsson E, Lindh C, Sennerby L. Bone regeneration using a hollow hydroxyapatite space-maintaining device for maxillary sinus floor augmentation – a clinical pilot study. *Clin Implant Dent Related Res*. 2012; 14:575–584. <https://doi.org/10.1111/j.1708-8208.2010.00293.x> PMID:20586781
- Porth, CJ, Bamrah VS, Tristani FE, Smith JJ. The Valsalva Maneuver: Mechanisms and Clinical Implications. *The Journal of Critical Care*. 1984; 13: 507–518.
- Srouji S, Kizhner T, Ben David D, Riminucci M, Bianco P, Livne E. The Schneiderian membrane contains osteoprogenitor cells: in vivo and in vitro study. *Calcif Tissue Int*. 2009; 84:138–145. <https://doi.org/10.1007/s00223-008-9202-x> PMID:19067018
- Srouji S, Ben-David D, Lotan R, Riminucci M, Livne E, Bianco P. The innate osteogenic potential of the maxillary sinus

- (Schneiderian) membrane: an ectopic tissue transplant model simulating sinus lifting. *Int J Oral Maxillofac Surg.* 2010; 39: 793–801. <https://doi.org/10.1016/j.ijom.2010.03.009> PMID:20417057
24. Scala A, Botticelli D, Rangel IG, De Oliveira JA, Okamoto R, Lang NP. Early healing after elevation of the maxillary sinus floor applying a lateral access: a histological study in monkeys. *Clin Oral Implants Res.* 2010; 21:1320–1326. <https://doi.org/10.1111/j.1600-0501.2010.01964.x> PMID:20637033
25. Scala A, Botticelli D, Faeda RS, Garcia Rangel Jr, Américo de Oliveira J, Lang NP. Lack of influence of the Schneiderian membrane in forming new bone apical to implants simultaneously installed with sinus floor elevation: an experimental study in monkeys. *Clin Oral Implants Res.* 2012; 23:175–181. <https://doi.org/10.1111/j.1600-0501.2011.02227.x> PMID:21668505
26. Proussaefs P, Lozada J. Use of Titanium Mesh for Staged Localized Alveolar Ridge Augmentation: Clinical and Histologic-Histomorphometric Evaluation. *The Journal of Oral Implantology.* 2006; 32: 237–247. [https://doi.org/10.1563/1548-1336\(2006\)32\[237:UOTMFS\]2.0.CO;2](https://doi.org/10.1563/1548-1336(2006)32[237:UOTMFS]2.0.CO;2)
27. Xu H, Shimizu Y, Asai S, Ooya K. Grafting of deproteinized bone particles inhibits bone resorption after maxillary sinus floor elevation. *Clin Oral Implants Res.* 2004; 15:126–133. <https://doi.org/10.1111/j.1600-0501.2004.01003.x> PMID:14731186
28. Kim ES, Kang JY, Kim JJ, Kim KW, Lee EY. Space maintenance in autogenous fresh demineralized tooth blocks with platelet-rich plasma for maxillary sinus bone formation: a prospective study. *Springerplus.* 2016; 5: 274. <https://doi.org/10.1186/s40064-016-1886-1> PMID:27047706 PMCid:PMC4779789
29. Kim YK, Yun PY, Kim SG, Kim BS, Ong JL. Evaluation of Sinus Bone Resorption and Marginal Bone Loss after Sinus Bone Grafting and Implant Placement. *Oral Surgery, Oral Medicine, Oral Pathology, Oral Radiology, and Endodontics.* 2009; 107: e21–28. <https://doi.org/10.1016/j.tripleo.2008.09.033> PMID:19138634
30. Traxler H, Windisch A, Geyerhofer U, Surd R, Solar P, Firbas W. Arterial Blood Supply of the Maxillary Sinus. *Clinical Anatomy (New York, N.Y.).* 1999; 12: 417–421. [https://doi.org/10.1002/\(SICI\)1098-2353\(1999\)12:6<417::AID-CA3>3.0.CO;2-W](https://doi.org/10.1002/(SICI)1098-2353(1999)12:6<417::AID-CA3>3.0.CO;2-W)
31. Tarnow DP, Wallace SS, Froum SJ, Rohrer MD, Cho SC. Histologic and Clinical Comparison of Bilateral Sinus Floor Elevations with and without Barrier Membrane Placement in 12 Patients: Part 3 of an Ongoing Prospective Study. *The International Journal of Periodontics & Restorative Dentistry.* 2000; 20: 117–125.
32. Tawil G, Mawla M. Sinus Floor Elevation Using a Bovine Bone Mineral (Bio-Oss) with or without the Concomitant Use of a Bilayered Collagen Barrier (Bio-Gide): A Clinical Report of Immediate and Delayed Implant Placement. *The International Journal of Oral & Maxillofacial Implants.* 2001; 16: 713–21. PMID:11669254
33. Kim SM, Park JW, Suh JY, Sohn DS, Lee JM. Bone-Added Osteotome Technique versus Lateral Approach for Sinus Floor Elevation: A Comparative Radiographic Study. *Implant Dentistry.* 2011; 20: 465–470. <https://doi.org/10.1097/ID.0b013e31823545b2> PMID:22071497
34. Hallman M, Cederlund A, Lindskog S, Lundgren S, Sennerby L. A clinical histologic study of bovine hydroxyapatite in combination with autogenous bone and fibrin glue for maxillary sinus floor augmentation. Results after 6 to 8 months of healing. *Clin Oral Implants Res.* 2001; 12:135–143. <https://doi.org/10.1034/j.1600-0501.2001.012002135.x> PMID:11251663
35. Uzbek UH, Rahman SA, Alam MK, Gillani SW. Bone Forming Potential of An-Organic Bovine Bone Graft: A Cone Beam CT study. *J Clin Diagn Res.* 2014; 8 (12):ZC73-6. <https://doi.org/10.7860/jcdr/2014/8557.5352>
36. Testori T, Wallace SS, Trisi P, Capelli M, Zuffetti F, Del Fabbro M. Effect of xenograft (ABBM) particle size on vital bone formation following maxillary sinus augmentation: a multicenter, randomized, controlled, clinical histomorphometric trial. *Int J Periodontics Restorative Dent.* 2013; 33: 467-75. <https://doi.org/10.11607/prd.1423> PMID:23820706
37. Panagiotou D, Özkan Karaca E, Dirikan İpçi Ş, Çakar G, Olğaç V, Yılmaz S. Comparison of two different xenografts in bilateral sinus augmentation: radiographic and histologic findings. *Quintessence Int.* 2015; 46: 611-619. PMID:25699296
38. Lutz R, Berger-Fink S, Stockmann P, Neukam FW, Schlegel KA. Sinus floor augmentation with autogenous bone vs. a bovine-derived xenograft - a 5-year retrospective study. *Clin Oral Implants Res.* 2015; 26:644-648. <https://doi.org/10.1111/clr.12352> PMID:25906198
39. Papadogeorgakis N, Prokopidi ME, Kourtis S. The use of titanium mesh in sinus augmentation. *Implant Dent.* 2010; 19:109-114. <https://doi.org/10.1097/ID.0b013e3181d46a0c> PMID:20386213
40. Leblebicioglu B, Ersanli S, Karabuda C, Tosun T, Gokdeniz H. Radiographic evaluation of dental implants placed using an osteotome technique. *J Periodontol.* 2005 ;76:385-390. <https://doi.org/10.1902/jop.2005.76.3.385> PMID:15857072