

Evaluation of Scoliosis Deviation with Clinical Measurements during Physical Therapy

Elizabeta Popova Ramova¹, Anastasica Poposka², Milica Lazovic³, Leonid Ramov¹

¹Department for Physical Therapy Education, University "St. Kliment Ohridski", Bitola, Republic of Macedonia; ²Orthopedic Clinic, Medical Faculty, Skopje Republic of Macedonia; ³Clinic for Rehabilitation, Medical Faculty Nis, Republic of Serbia

Abstract

Citation: Popova Ramova E, Poposka A, Lazovic M, Ramov L. Evaluation of Scoliosis Deviation with Clinical Measurements during Physical Therapy. *Maced J Med Sci.* 2013 Mar 15; 6(1):31-36. <http://dx.doi.org/10.3889/MJMS.1857-5773.2013.0277>.

Key words: scoliosis; evaluation; therapy; physical; measurements.

***Correspondence:** Elizabeta Popova Ramova, PhD. Department for Physical Therapy Education, University "St. Kliment Ohridski" Bitola, Vasko Karangeleski str. NN 7000 Bitola, R. Macedonia. Email: betiramova62@yahoo.com

Received: 01-Nov-2012; **Revised:** 24-Jan-2013; **Accepted:** 24-Jan-2013; **Online first:** 19-Feb-2013

Copyright: © 2013 Popova Ramova E. This is an open-access article distributed under the terms of the Creative Commons Attribution License, which permits unrestricted use, distribution, and reproduction in any medium, provided the original author and source are credited.

Competing Interests: The author have declared that no competing interests exist.

Aim: Scoliosis is a 3D deformation, in a vast related medical literature, we can find quite a few scoliosis evaluation indices, which are based on back surface data and are generally measured along three planes. The purpose of this study was to assess the usefulness of surface clinical measurements for evaluation of condition by patients with scoliosis in shorter terms.

Materials and Method: A total of 40 scoliosis patients, with an average age of 13 years, the average Risser sign 3 and an average angle of curvature of 23.67° according to Cobb were included in this study. In research we were looking for a correlation between convexity of curve by x-ray picture and asymmetry of measurement distances.

Results: The data analysis is showing a correlation between decrease of clinical asymmetry and reduction of curve by treatment with significance $p < 0.01$. The trunk surface asymmetry is still difficult to objectify and it depended on new examination techniques shall be done more.

Conclusion: External measurements of some anatomical points can be used in physical therapy practice for evaluation of condition by patients with scoliosis with significant correlation of convexity of curve.

Introduction

Scoliosis is characterized by lateral deviation of the spine. In a vast related medical literature, one can find a few scoliosis evaluation indices, which are based on back surface data and are generally measured along three planes [1].

Our interest of study was how we can use the trunk surface (TS) measurements in evaluation of condition by treatment with exercises. TS symmetry is also one of the elements intergrading and improving the quality of life of patients, an issue vital for any human being. TS analysis can help document the external asymmetry associated with different types of spinal curves in scoliosis as well as the cosmetic improvement obtained after treatment with exercises [2].

The evaluation of TS metrics used as Scoliosis or any deformity evaluation indices can be very useful and can offer some objective accessing tools for the interested physicians [3].

Scoliosis screening practice is important activity for each physician who likes to treat this deformity. The goal of scoliosis screening is to detect scoliosis in an early stage. When the deformity is likely to go unnoticed and there is an opportunity for a less invasive method of treatment. What in reality scoliosis school screening program does? It is using the scoliometer, clinical tests, or any other surface measuring device. It does not reveal the scoliosis per se. There is a significant correlation between clinical deformity and radiological picture, but with surface topography or other technique the standard deviation is so high that it is not possible to predict the degree of curvature from them [4, 5]. Following the treatment

outcomes for 3-6 months it's not good to repeat x-ray expository especially for curve with small size.

The gold standard for idiopathic scoliosis diagnosis is x-ray imaging, however children are not exposed to it for screening purpose or for evaluation of bad posture, because of the radiation risk [6, 7]. All surface topography and other surface methods are based on external body contour assessment which can be performed with the use of several techniques. Surface technique is usually performed in standing erect position, same like x-ray examination, but it is not possible to make them in trunk forward flexion like in Adam's test. The all techniques are based on interference of grids projected onto subjects back. They are not giving us quantitative measurements [8-10].

The purpose of this study was to access the usefulness of surface clinical measurements of some anatomical points for evaluation of condition by patients with scoliosis spine deviation in shorter terms.

Material and Method

The prospective study was done at the physical therapy department with permission of examination and treatment of children from parents. The following inclusion criteria were: 1) diagnosis of scoliosis spine deviation, 2) first checkup and four controls in a period of 12 months with clinical tests and measurements, 3) no other treatment than exercises, 4) AP and profile radiography taken not earlier than 12 months of first.

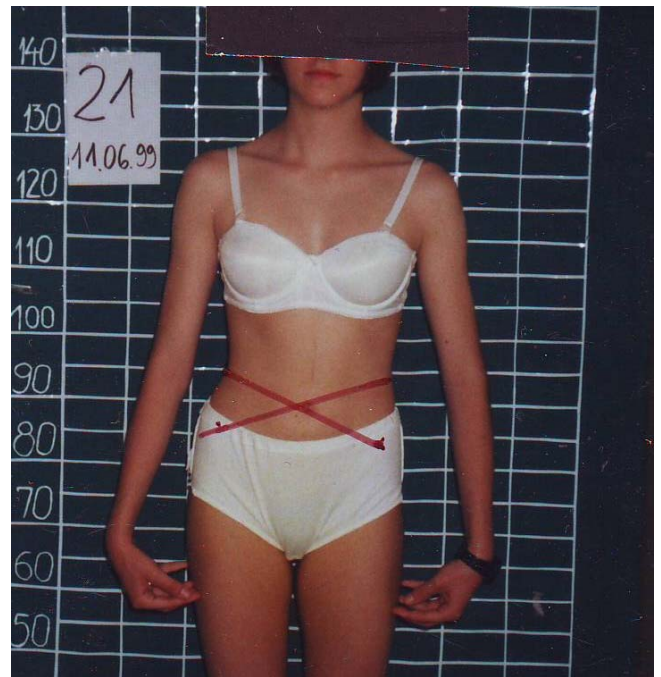


Figure 2: Clinical measurements of lorences distances before treatment.

A total of 40 scoliosis patients, with an average age of 13 years, the average Risser sign 3 and an average angle of curvature of 23.67° according to Cobb were included in this study. The Cobb angle of all curves was measured in standardized way on radiography.

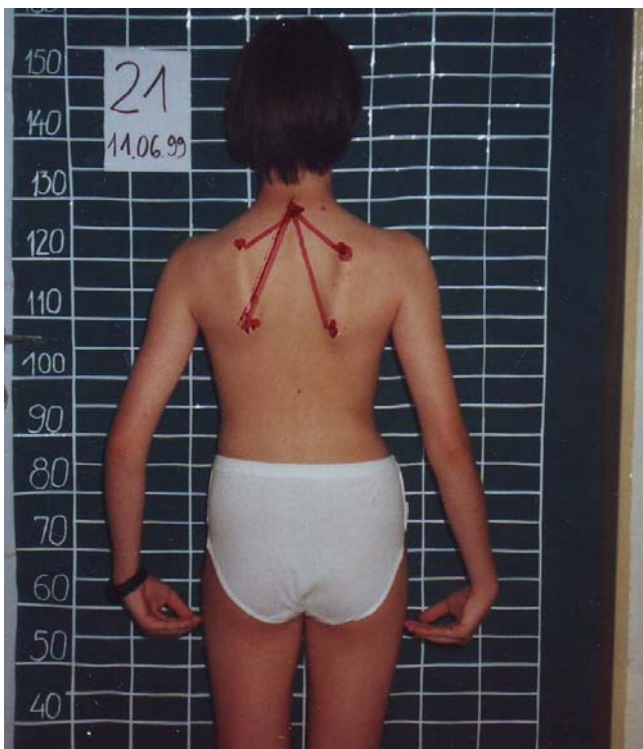


Figure 1: Clinical measurements of scapula distances before treatment.

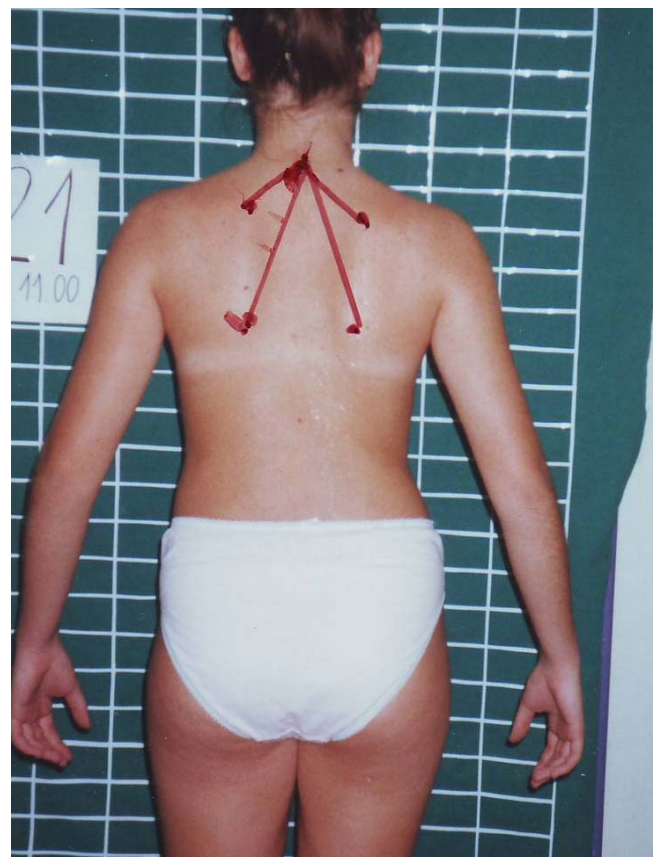


Figure 3: Clinical measurements of scapula distances after treatment.

In our research we were looking a correlation between Cobb angle of curve by x-ray picture and asymmetry of measurement distances. The distances were measuring with tailor meter. This way of measuring needs good experience and training. The distance is measured in standard position on the surface of the back. The measuring distances on back are: left and right distance from procesus spinosus of C7, to angle medialis of scapula and angle inferior of scapula on the most prominent point. The child is in standing position with arms behind body and foot in parallel position and distance of 5 cm. between them.

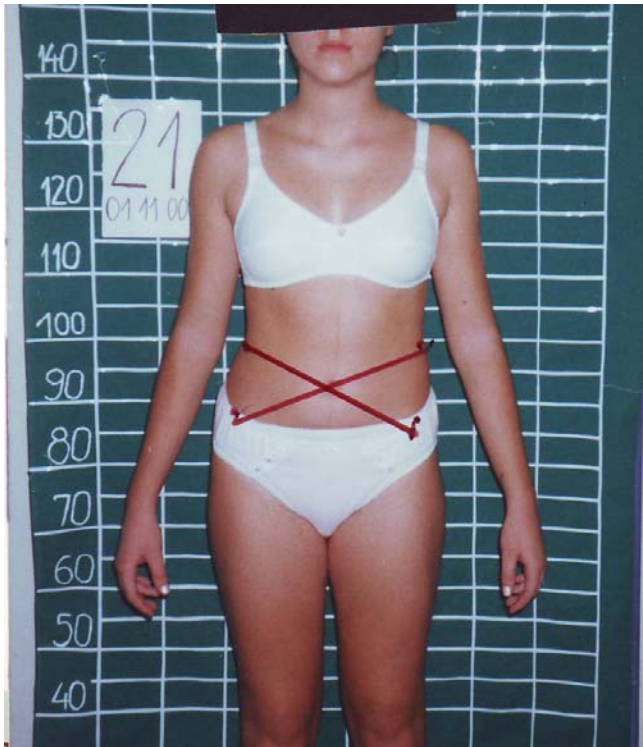


Figure 4: Clinical measurements of Lorence's distances after treatment.

The distance from apex of Lorence's triangle to contralateral spina iliaca anterior superior is making to follow way: the spina iliaca anterior superior from the most prominent point to the apex of Lorence's triangle at the medial axilar line. These three measurements are repeating three times, from both sides and then we make average.

The clinical measurements was made five times in standing erect position, showing in Figure 1-4, 1 and 3 before treatment and 2 and 4 after six month of treatment. The way of measurement is showing in Figure 5.

All patients had Schrot's exercises program with four courses of 10 days at the physical therapy department and same program at home during whole year.

Analysis of the statistical data was done with the statistical program STATISTICA 6 and Microsoft Office Excel 7. The nominal analysis was done frequency of positive and negative correlation of asymmetry with convexity of curve and percentage

presence. For descriptive analyses of the presence of the frequencies per examination of coefficient of correlation with significance of $p < 0.01$ were used.

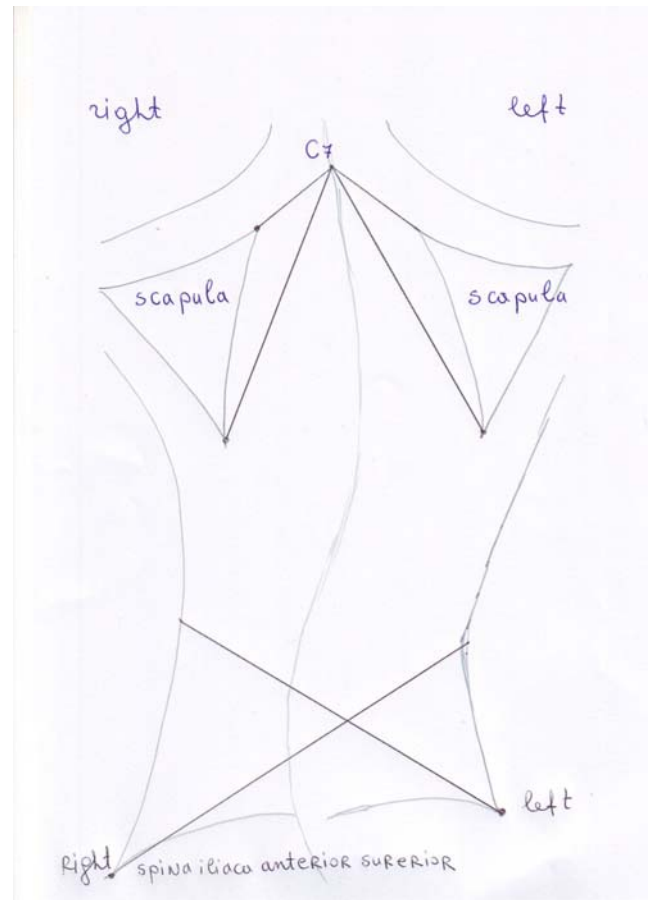


Figure 5: Figures of clinical measurements by each patient and scoliosis curve.

Results

The systematic checkups take a primary significance to detection of the deformities of spinal column as the most of the patients were without significant difficulties. The results showed a significant connection between the clinical examinations (pelvis asymmetry, asymmetry of Lorence's triangle, shoulder-height differences, scapula asymmetry).

The results from scapula asymmetry and shoulder-height are showing in Table 1.

Table 1: The correlation between convexity of curve by x-ray and shoulder-height.

Shoulder height	Convexity of curve left	Convexity of curve right
Left	18	11
Right	2	9
Total	20	20

From the results of Table 1 we can see that by 27(67.5%) of patients shoulder-height is in correlation with convexity of the curve, with correlation analyze $p < 0.01$ and $R = +1$, there is significant.

Table 2 is showing the results from scapula asymmetry measurement and greater distances on the convexity of the curve. The 24 (60 %) of the patients have increase C7 distances at the convexity of the curve. With correlation analyze it is $p < 0.01$, $R = +0.99$, it is significant.

Table 2: Greater scapula asymmetry and convexity of the curve.

Scapula asymmetry	Frequency	%
Increase distance on convexity	24	60
Increase distance on concavity	10	25
Without asymmetry	6	15
Total	40	100

The distribution of patients with pelvis fall dawn side and contra lateral decrease Lorence's triangle are showing in Table 3. The 31 (77.5%) of patients have a correlation between pelvis fall of the convexity of the curve and decrease of Lorence's triangle at the opposite site, and it is significant $p < 0.01$ $R = +0.99$.

Table 3: Correlation between convexity of curve and decrease of Lorence's triangle at the opposite site.

Fall down pelvis Convexity of curve	Decrease Lorence's triangle opposite site left	Decrease Lorence's triangle opposite site right
Left n=26	4	22
Right n=11	9	2
Same level	/	3
Total n=40	13	27

At the end of the treatment the reduction of curve by x-ray picture was compared with decrease of left right asymmetry by clinical measurements of the distances. The results are showing in Table 4. By 32 (80%) of the patients, reduction of the curve by x-ray picture 30 (75%) is in correlation with reduction of clinical asymmetry and progression of curve 2 (5%) is in correlation with increase of asymmetry.

Table 4: Correlation between reduction of curve and reduction of clinical asymmetry by treatment.

Radiological result of curve	Increase left/right asymmetry	%	Decrease left/right asymmetry	%
Reduction of curve	3	7.5	30	75
Progression of curve	2	5	5	12.5

Discussion

Understanding scoliosis or other trunk asymmetry is a complex issue since it evolves in three dimensional spaces. Many technologies have been developed and used over the years and each technology offers new approaches in understanding and describing scoliosis through different set of indices [11, 12].

Out of this massive data the scientific society has to choose measures and define methodologies in order to optimally diagnosis, quantify, document and

assess the progression or reduction of scoliosis for both clinical treatment and cosmetic improvement [13, 14].

Unfortunately, currently, a general consensus on a set of indices does not exist. It is clear that surface metrics have very little correlation to Cobb angle measurements. In our study was analyzing the correlation between convexity of the curve and asymmetry of skin surface measurable distances [15, 16].

Scoliometer is using for standard measurement of back shape by scoliosis, but his measurements are not with correlation of spine curve by x-ray pictures, specially because there are two different positions of the measurement [9].

The clinical tests of upper arm, bending test and test by Mathias are only clinical qualitative measurements and can be positive or negative. They are not significant for diagnosis of scoliosis because have many lack of it. There are explaining in consulting studies [17-20].

The reduction of asymmetry was in correlation with reduction of curve like an effect of applying treatment. These distances based on direct measurements are more accurate than only to use clinical test like positive or negative.

There are many surface methods, which are using for school screening examination of spine deformity [21-24]. They are not with correlation between trunk asymmetry and cob angle and there is risk of obtaining false negativity is low (high sensitivity) but false positivity is high (low specificity) of those methods of examinations [25-29]. There is one quantitative method with spine mouse device, and we have personal experiences with it, but it is significant only for spine deformity in sagital plane [30-32].

Our way of measuring is based on some before researches that convexity of lumbal spine is with correlation of pelvis fall, by thoracic lumbar scoliosis, and the upper arm and scapula asymmetry is with correlation of scoliosis deviation [33-35]. Our TS measurement is only for existing asymmetry of Lorence's triangle and pelvis tilting in thoracic lumbar scoliosis. It is a correlation between clinical and radiographic findings before and after 12 months of treatment.

Grivas et al. [5] need all the examinations and clinical test to be done in sitting position, because it is more significant from the standing. To objective the position of scapula was made metal land markers in x-ray examination. The use of constant system through points on the back ground creates major technical problems, and Grivas et al. [36] suggested the examination to be done in specific coordinate system in which case stable anatomical landmarks are necessary. The same anatomical land markers have been used by many researches, as for example [37-

39]. The landmarks diameter of 6 mm was attached to each spinous process from Th1 to L5 in similar study like our [40]. They have used 12 metrics for the 3-D surface data. We have used 6 metrics, 3 for right and 3 for left side in frontal plane from frontal and back side. This statement is not perfectly sure because of fact that anatomical clinical measurements have not compare with radiological measurements with landmarks.

It should be clear that indices measured on different plane do not correlate to each other. Examples are Cobb angle vs. Scoliometer angle, Cobb vs. Rib and flank prominences. etc. there are conclusions from consulting studies [17-40].

In deficit of scoliometer and in wish to evaluate the effect of treatment at home, in short period of three months we have used this model of clinical measurements by scoliosis with indication for treatment with exercises.

In conclusion, it could be said that the trunk surface asymmetry is still difficult to objectify and it is depended of new examination techniques. In deficit of equipment and in daily practice it was made with many indices but there are not high significant compare with x-ray pictures. Our external measurements of some anatomical points of trunk and body can be use in physical therapy practice for evaluation of condition by patients with scoliosis spine deformation with significant correlation of convexity of curve. Determination of curve convexity is important for planning the exercises program by asymmetric exercises like in Schort's method.

References

- Grivas TV, Vasiladis ES, Mihos C, et al. Trunk asymmetry in juveniles. *Scoliosis*. 2007;2(1):34.
- Pazos VF, Cherié J, Danaserau J et al. Reliability of trunk Shape measurements based 3-D surface. *Reconstructuions. Eur-Spine J*. 2007;16:1882-91.
- Nault ML, Allard P, Hinse S, Le Blanc R, Caron O, Labelle H, Sadeghi H. Relations between standing stability and body posture parameters in adolescent idiopathic scoliosis. *Spine (Phila Pa 1976)*. 2002;27(17):1911-7.
- Bunnell WP. Selective screening for scoliosis. *Clin Orthop Relat Res*. 2005;(434):40-5.
- Grivas TB, Vasiliadis ES, Koufopoulos G, Segos D, Triantafyllopoulos G, Mouzakis V. Study of trunk asymmetry in normal children and adolescents. *Scoliosis*. 2006;1:19.
- Cassar-Pullicino VN, Eisenstein SM. Imaging in scoliosis: what, why and how? *Clin Radiol*. 2002;57:543.
- Grivas TB, Daggas S, Polyzois BD et al. The double rib contour sign (drsc) in lateral spinal radiographs. Aetiologic implications for scoliosis? *Stud Health Technol Inform*. 2002;88:38-43.
- Goldberg CJ, Kalisz M, Moore DP et al. Surface Topography, cob angles and cosmetic change in scoliosis. *Spine*. 2001;26(4): E55-E63.
- Grossman TW, Mazur JM, Cummings RJ. An evaluation of the Adams forward bend test and the scoliometer in a scoliosis school screening setting. *J Pediatr Orthop*. 1995;15:535.
- Minquez MF, Buendia M, Cibrian RM et al. Quantifier variabies of the back surface deformity obtained with a noninvasive structured diagnosis. *Eur Spine J*. 2007;16(1):73-82.
- Kotwicki T, Negrini S, Grivas TH et al. Methodology of evaluation of morphology of the spine and trunk in idiopathic scoliosis and other spinal deformities-6th SOSORT consensus paper. *Scoliosis*. 2009;4:26.
- Zaina F, Negrini S, Atanasio S. TRACE (Trunk Aesthetic Clinical Evaluation) a routine clinical tool to evaluate aesthetics in scoliosis patients: development from the Aesthetic index (AI) and repeatability. *Scoliosis*. 2009;4:3.
- Zaina F, Negrini S, Atanasio S. TRACE (Trunk Aesthetic Clinical Evaluation), a routine clinical tool to evaluate aesthetics in scoliosis patients: development from the Aesthetic index (AI) and repeatability. *Scoliosis*. 2009;4:3.
- Jaremko JL, Poncet P, Ronsky J et al. Indices of torso asymmetry related to spinal deformity in scoliosis. *Clin Biomech*. 2002;17(8):559-68.
- Kotwicki T. Evaluation of scoliosis today: examination x-rays and beyond. *Disabil Rehabil*. 2008;30(10):742-51.
- Allard P, Chavet P, Barbier F, et al. Effect of body morphology on standing balance in adolescent idiopathic scoliosis. *Disabil Rehabil*. 2008;30(10):763-71.
- Negrini A, Negrini S. The tree-dimensional easy morphological (3-demo) classification of scoliosis part IV: repeatability. *Scoliosis*. 2006;1:23.
- Burwell RG, Aujla RK, Freeman BJC et al. Patterns of extra spinal left-right skeletal asymmetries in adolescent girl with lower spine scoliosis: relative lengthening of the ilium on curve concavity and of right lower limb segments. *Spine*. 2000;15(18):2358-63.
- Smania N, Picelli A, Romano M et al. Neurophysiological basis of rehabilitation of AIS. *Disabil Rehabil*. 2008;30(10):763-71.
- Karissou A, Frykberg G. Correlations between force plate measurs for assessment of balance. *Clin Biomech (Bristol, Avon)*. 2000;15(5):365-9.
- Zubovic A, Davies N, Berryman F et al. New method of scoliosis deformity assessment: ISIS2 system. *Stud Health Technol Inform*. 2008;140:157-60.
- Ovaida D, Bar-On E, Fragniere B et al. Radiation free quantitative assessment of scoliosis: a multi center prospective study. *Eur Spine J*. 2007;16(1):27-105.
- Shannon TM. Development of an apparatus to evaluate adolescent idiopathic scoliosis by dynamic surface topography. *Stud Health Technol Inform*. 2008;140:121-7.
- Goldberg CJ, Grove D, Moore DP et al. Surface topography and vectors: a new measure for the three dimensional quantification of scoliosis deformity. *Stud Health Technol Inform*. 2006;123:449-55.
- Oxborrow, N. Assessing the child with scoliosis: the role of surface topography. *Arch Dis Child*. 2008;3:453-55.
- Ajembo PO, Durdle NG, Raso VJ. Characterizing torso shape deformity in scoliosis using structured splines models. *IEEE Trans Biomed Eng*. 2009;56(6): 1652-62.
- Hresko MT, Mesiha M, Richards K et al. A comparison of methods for measuring spinal motion in female patients with adolescent idiopathic scoliosis. *J Pediatric Orthop*. 2006;26(6):758-63.
- Kotwicki T, Kinel J, Chowanska A et al. POTSI, Hump Sum and Sum of Rotation-new surface topography parameters for evaluation of scoliosis deformity of the trunk. *Fizioterapija Polska*. 2008;3(4):231-40.
- Ajembo PO, Durdle NG, Hill D, et al. Classifying torso deformity in scoliosis using orthogonal maps of the torso. *Med Biol Eng Comput*. 2007;45(6):575-84.
- Ripani M, Cesare A, Giombin L et al. Spinal curvature: comparison of frontal Measurement with the spinal mouse and radiographic assessment. *J Sport med Phys fitness*. 2008;48(4):488-94.
- Keliss E, Adamou G, Tzilos G et al. Reliability of Spinal range of motion in healthy boys using skin surface device. *J Manipulative physical Ther*. 2008;31(8):570-8.
- Popova Ramova E, Poposka A, Lazovic M. School Screening for Bad Posture with Spine Mouse Device. *Maced J Med Sci*. 2010;3(4):358-363.
- Heine J. Die Lumbalskoliose. Enke, 1980.
- Heine J. Clinical aspects of lumbar scoliosis. 1st European congress on scoliosis and kyphosis. Dubrovnik, 1983:144.

35. Patias P, Grivas TB, Kaspiris A et al. A review of the trunk surface metrics used as Scoliosis and other deformities evaluation indices. *Scoliosis*. 2010;5:12.
36. Cassar-Pullicino VN, Eisenstein SM. Imaging in scoliosis: what, why and how?. *Clin Radiol*. 2002;57:543.
37. Bendels G, Klein M, Samini A et al. Statistical shape analysis for computer aided spine deformity detection. *Journal of WSCG*. 2005;13.
38. Duong L, Mac-Thiong JM, Labelle H. Real time noninvasive assessment of external trunk geometry during surgical correction of adolescent idiopathic scoliosis. *Scoliosis*. 2009;4:5.
39. Patias P, Stylianidis E, Peteraki M et al. 3D digital photogrammetric reconstructions for scoliosis screening. *Proceeding of the ISPRS Com.V Symposium, dresden, Germany. The International Archives of the Photogrammetry, remote Sensing and Spatial Information Sciences*. 2006;36(5).
40. Thometz J, Liu X, Lyon R et al. Variability in Three-Dimensional Measurements of Back Contour with Raster Stereography in Normal Subjects. *Journal of Pediatric Orthopedics*. 2000;20:1:54.