***Maced J Med Sci* electronic publication ahead of print,**
published on January 31, 2011 as doi:10.3889/MJMS.1857-5773.2011.0156

Macedonian Journal of Medical Sciences.
doi:10.3889/MJMS.1857-5773.2011.0156
Basic Science

OPEN ACCESS

Some Anatomic-Topographic Features of Common and Right Hepatic Ducts and their Constituents

Dragica Jurkovikj

Institute of Anatomy, Medical Faculty, University "Ss Cyril and Methodius", Skopje, Republic of Macedonia

Citation: Jurkovikj D. Some Anatomic-Topographic Features of Common and Right Hepatic Ducts and their Constituents. Maced J Med Sci. doi.10.3889/MJMS.1957-5773.2011.0156.

Key words: liver; anatomy; topography; bile ducts; portal vein.

Correspondence: Dr. Dragica Jurkovikj. Medical Faculty, Institute of Anatomy, 50 Divizija, No. 16, 1109 Skopje, Republic of Macedonia. Phone: +38923125304.
E-Mail: dragica.jurkovik@gmail.com

Received: 27-May-2010; Revised: 31-Oct-2010; Accepted: 01-Nov-2010; Online first: 31-Jan-2011

Competing Interests: The author have declared that no competing interests exist.

Abbreviations: RP- right portion; LP-left portion; P-profound; S-superficial; cp-caudate process; H-hilar; dc-cystic duct; RDS- b, c, d-right dorsal sector subsegments b, c, d; pp-papillar process; MRC-magnetic resonance cholangiography; MRCP-magneticresonance cholangiopancreatography; Mn-DPDP-mangafodipir trisodium; MR-magnetic resonance; PSC-primary sclerosing. cholangitis.

Abstract

Aim. Anatomic-topographic features of the common duct and ducts of the right functional liver are attributes of the diagnostic-surgical and transplantation liver practice. In connection with this notion, this study has analyzed the intrahepatic schemes of branching of portal vein, hepatic artery and bile ducts on 4casts, and branching of only portal vein and bile ducts on another 9casts, all of which being prepared with the injection-corrosion method.

Material and Methods. The material was obtained from post-mortem human specimens of adult individuals of both sexes.

Results. The observation of the casts showed a modal and aberrant type of forming of common hepatic duct at the level of the hilum or at the lower extrahepatic level. The right hepatic duct may be absent, may be with a short bifurcation form and rarely with a significant length. Of the sectorial ducts, the trunk of the posterior duct is most commonly longer than that of the anterior one, and rarely equivalent. Usually the anterior duct lies lower and in a more anterior position, except in 1 case of infraportal position of the posterior duct in relation to the anterior branch of the portal vein. Accessory ducts have also been detected and they originated from profound parenchyma, but also supraparenchymal from the subvesical and subcapsular connective tissue.

Conclusion. Common hepatic duct has shown modal and aberrant type of forming at the level of the hilum or at a lower extrahepatic level.

Introduction

Clinical literature very often presents description of two right ducts of the biliary tree as well as an aberrant or accessory segmental drainage with extrahepatic confluence. The limitations of the diagnostic methods MRC [1], MRCP [2], Mn-DPDP MRC [3], Mn-DPDP MRC versus conventional T2-weighted MR cholangiography [4] in portraying and interpretation of biliary anatomy and application of non-dilated bile ducts or peripheral intrahepatic ducts [5], supported by intraoperative cholangiography, were the motives of this study. Depending on the minimal detectable caliber of the ducts [6] and their condition (non-dilated or dilated) in certain diseases of the bile ducts (PSC, cholangiopathy), they could be visualized until the third order of ducts [7].

Examination of the biliary anatomy is also of benefit to the developmental methods for living donor liver transplantation (LDLT) in adults requiring either a right or left hepatectomy in order to supply sufficient functional hepatic mass [8, 9].

Material and Methods

The material for this study included 13 post-mortem specimens of adult human liver of both sexes, (10 men, 3 women; age range 42-88 years) from September 1996 to December 2008. Injection-corrosion method has been applied. In 4 specimens portal vein, hepatic artery and biliary ducts have been injected, while in the remaining 9 specimens only portal vein and biliary ducts. Different odontologic colored acrylate was used for injection. The injected specimens were corroded in concentrated HCl acid. The obtained casts were washed out with tap water and then observed under light magnifying glass.

On the examined material an incomplete or different filling of porto-biliary elements, as a results of fibroobliterative lesions (so called pruning) typical to fibrosclerosing disease was found. In the four cases the segmental ducts were relatively shorter than the accompanied portal branches whereas in the others four cases they were predominantly longer owing to a shortening of the portal branches. The significant incomplete filling of segmental ducts-total, central, lobar, sectorial or segmental in the remains five cases was found. These features of filling of biliary ducts, as an accustomed morphology in adults, with schemes and pictures only to hilar part was shown.Intrahepatic schemes of branching of the injected elements were observed and particularly topographic relations of biliary elements versus portal ones and internal relationship of the right sectorial ducts.

The following items were determined:

For the common hepatic duct: a merging pattern, site of junction of constituent ducts in relation to the portal elements and forms of junction.

For the right hepatic duct: a merging pattern, site of junction of sectorial ducts in relation to the portal elements as well as an appearance and confluent pattern of sectorial duct trunks.

Presence of accessory ducts: their origin, way and site of confluence.

Results

Common Hepatic Duct (CHD)

Merging pattern. Two types of merging pattern of CHD were observed on the examined casts.

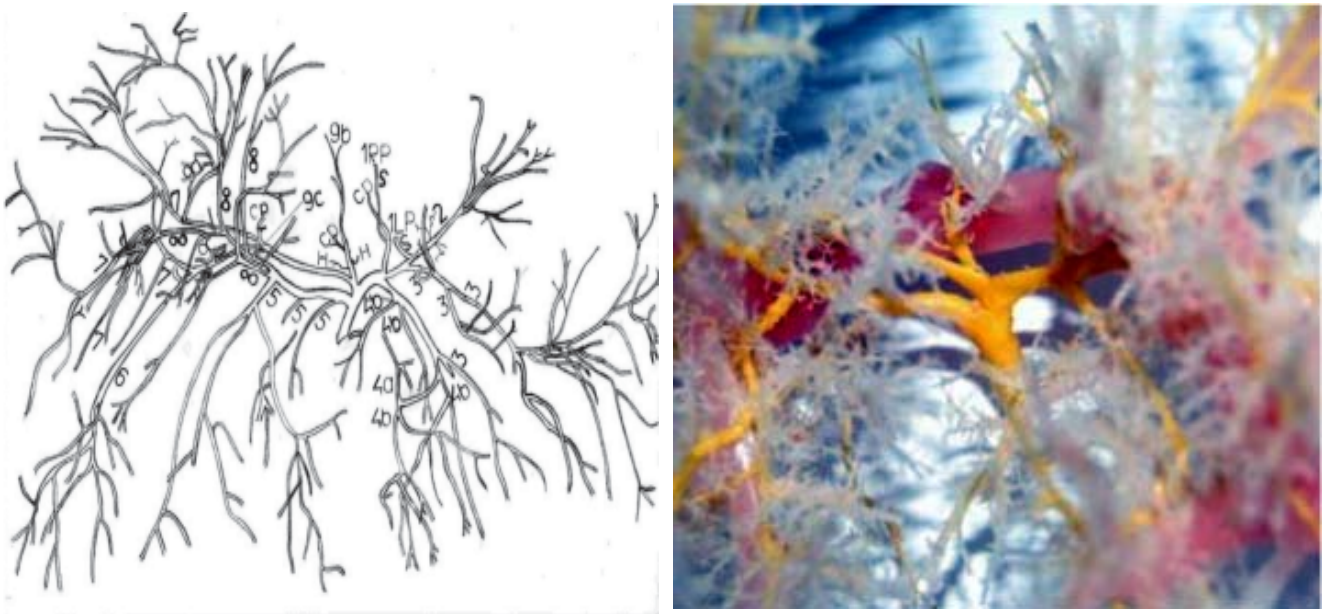

Figure 1: RPD- medium long arch-like duct with mild convexity directed forward and upward. RAD- medium long sinusoidal duct with convexity to the right, downward and backward, but terminally upward and forward. RAD emerges at the level of the initial part of RPD, but at a significant distance anteriorly. The confluence is at an acute angle of RAD with the terminal part of LHD; the angle is open to the right, and the terminal part of RAD is anterior and below to the same part of RPD (left). Anterior view of cast: UBC, LHD, RPD, RAD and CHD (right).

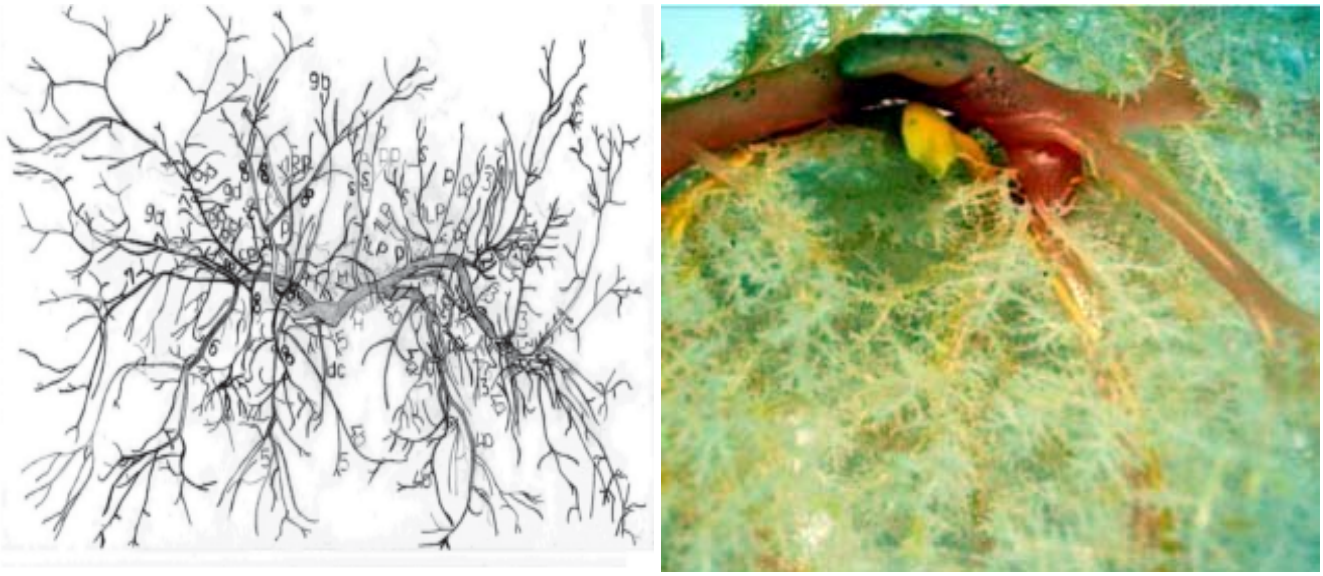

Figure 2: RPD- medium long arch with convexity being directed upward. RAD- medium long arch with convexity to the right downward. RAD emerges above the level of the left 1/3 of RPD, at a significant distance anterior and at this level they apparently cross each other. The confluence is at an acute angle open to the right and forward; the terminal part of RAD is anterior to the same part of RPD (left). Posterior-inferior view of cast:UBC, LHD, RHD, CHD, accessory ducts, RPD and RAD (right).

Type 1. Normal (modal) type of merging pattern from the right hepatic duct (RHD) and left hepatic duct (LHD) in 8 cases (61.5%), Figures 2,3,5 (left), Figure 3 (right).Type 2. Aberrant type of merging pattern from the left hepatic duct, which has previously accepted as a tributary the right posterior (sectorial) duct (RPD) and the right anterior (sectorial) duct (RAD) in 5 cases (38.5%), Figures 1 and 4 (left).

The site of junction [Upper biliary confluence (UBC)] in relation to the portal elements in porta hepatis is:

In front of the portal bifurcation. In relation to anterior margins of the hilar part of the right and left portal branch, UBC lies immediately below the level of the mentioned margins in 2 cases (15.4%) Fig. 2; immediately above the level of the mentioned margins in 1 case (7.7%) In front of the portal trunk, below the level of the anterior margins of the portal right and left branch in 4 cases (30.76%)

In front of the left portal vein branch, below the level of the anterior margin of the initial part of the mentioned branch in 4 cases (30.76%) Fig. 1 and 3; above the level of the same part in 1 case (7.7%) In front of the right portal vein branch, below the level of the anterior margin of the initial part of the mentioned branch in 1 case (7.7%)

Forms of junction

In cases with modal type of forming, the right and left hepatic ducts merge to form a common hepatic duct in a manner as follows: at an acute angle (1 case - 7.7%) or at a right angle (1 case - 7.7%), at the level of the hilum confluent one to another; at an acute angle, at the level of the hilum, the right hepatic duct receives the left hepatic duct as a lateral branch (1 case - 7.7%) (Fig. 3); at an obtuse angle, at the level of the hilum, the left hepatic duct receives the right hepatic duct as a lateral tributary (1 case - 7.7%) [Fig. 2 (left)]; at an acute angle (1 case - 7.7%) or at a right angle (2 cases - 15.3%) (Fig. 5), below the level of the hilum confluent one to another; at an obtuse angle, below the level of the hilum, the right hepatic duct receives the left hepatic duct as a lateral tributary (1 case - 7.7%).

In cases with aberrant type of forming, posterior and anterior right sectorial ducts join consecutively the left hepatic duct in a manner as follows: the right anterior sectorial duct at an obtuse angle merges together with the left hepatic duct, which has previously received the right posterior sectorial duct as a lateral tributary almost at a right angle at the level of the hilum (1 case - 7.7%); the right anterior sectorial duct merges together with the left hepatic duct at an acute angle below the level of the hilum, while the left hepatic duct receives the posterior sectorial duct as a lateral tributary at an obtuse angle at the level of the hilum (1 case - 7.7%) (Fig. 4), that is,

Figure 3: RPD- long sinusoidal with convexity being directed backward, and then upward. RAD- medium long straight duct directed obliquely, downward to the left and backward. RAD emerges at the level of the second convexity of RPD, at a small distance anteriorly. The confluence is at an acute angle open to upward and to the right; the terminal part of RAD is anterior to the same part of RPD (left). Anterior view of cast:UBC, LHD, RHD, CHD, RPD and RAD (right).

below the level of the hilum (1 case – 7.7%) (Fig. 1); the left hepatic duct first receives as lateral parallel tributaries the right posterior sectorial duct at an obtuse angle at the level of the hilum (1 case - 7,7%), and below the level of the hilum also in 1 case - 7.7%, and then the right anterior sectorial duct at a right angle enters below the level of the hilum in both cases.

Right Hepatic Duct (RHD)

Merging pattern. Two types of forming pattern have been detected on the specimens with present RHD.

Type1. Normal (modal) type of merging pattern from the right posterior sectorial duct and right anterior sectorial duct in 7cases (53.8%), Fig. 2 and Fig. 3.

Type 2. Anomalous type of merging pattern where the common trunk of segmental duct 8 and segmental duct 5 joins with segmental duct 5, and the formed duct that is not RAD but RHD receives as tributaries RPD, 2 ducts from the right dorsal sector – 9b and a common trunk of 2 ducts of segment 5, in 1 case (7.7%), Fig. 5.

The site of junction in relation to the portal elements is: in front of the portal bifurcation in 1 case (7.7%); in front of the portal trunk, anterior to its left margin, 1 case (7.7%); anterior to its right margin, 1 case (7.7%); in front of the initial part of left portal vein branch, above the level of its anterior margin in 1 case (7.7%); anterior to middle part of the initial part of the mentioned branch in 1 case (7.7%) Fig. 3.

Below the anterior margin of right portal vein branch in 2 cases (15.4%) Fig. 2.

On the left side of the initial part of anterior portal vein branch in 1 case (7.7%) Fig. 5.

Forms of junction

In cases with a modal type of forming pattern of CHD and in 1 case of aberrant type, posterior and anterior right sectorial ducts merge to form right hepatic duct in a manner as follows:

At an acute angle, but with different length, appearance and confluent pattern of sectorial duct trunks which are shown on the intrahepatic complete schemes of branching. Proximal arch-like and distal sinusoidal: in two cases the angle is open to the right Fig. 1 (left), and in other one it is to the right and forward. Proximal sinusoidal, and distal arch-like: in one case the angle is open to the right and upward. Both proximal and distal ducts are arch-like: in one case the angle is open to the right. Both proximal and distal ducts are sinusoidal or arch-like and apparently crossed: in one case the angle is open to the right and in other one it is to the right and forward Fig. 2 (left).

Proximal duct is sinusoidal, and the distal straight: in one case the angle is open to upward and to the right Fig. 3 (left).

In cases of aberrant type of CHD forming (except for 1) and 1 case of modal type with absence of RAD, posterior and anterior right sectorial ducts join consecu-

tive the left hepatic duct in a manner as follows: in an acute angle, at a very short internal distance: in one case the angle is open to the right; at a right angle with terminal part of LHD: in two cases the angle is open to the right and upward Fig. 4 (left), and in other one it is to the right and backward; At a right angle with terminal part of RHD: in one case the angle is open to the right Fig. 5 (left).

Analysis of the relative length, appearance and common relation of the sectorial ducts for the samples of present RHD has shown that the posterior duct is longer than the anterior one, but it might be with a relatively same length; the right posterior sectorial duct is more often long sinusoidal, and rarely medium long or long arch-like, while the right anterior sectorial duct is more often arch-like (long, medium long and short) and rarely medium long sinusoidal, exceptionally medium long straight; the beginning of the trunk of the anterior duct compared with the same of the posterior duct is anteriorly in all 8 cases, at a significant or relatively small distance; compared on the frontal plane the trunk of the anterior duct emerges below the level of the posterior duct, above it or at the same level.

Usually the anterior duct stretches lower and anterior to the posterior duct, except in 1 case where the posterior duct passing under the anterior branch of the portal vein takes a lower position than the anterior, but is usually more posteriorly placed.

In the aberrant type of CHD forming, the anterior duct is anterior, but in 1 case the very confluence of the posterior duct is in front of the anterior.

Accessory Ducts

Observation of the molds revealed 3 cases where accessory ducts were determined, of which 2 have already been analyzed in a previously published study, but we are going to give a more detailed description of their location.

There is a subcapsular duct on the visceral surface that entered the posterior side of the right margin of CHD almost 1 cm below UBC. Initial ducts are draining from segment 5, one of them the superficial terminal part of caudate process, and the other profound to the right alongside the right half of vesicular fossa. The profound initial duct is accompanied by an artery, which initial part together with the posterior and anterior branches creates trifurcation of the right branch of the hepatic artery Jurkovikj [10].

There is a subvesical duct (duct of Luschka) with a left initial duct of subvesical tissue on the left-inferior half of the vesicular fossa (segment 4b), which crosses the main plane of division, and a right initial duct of subvesical tissue on the right half of the vesicular fossa (segment 5). The formed duct flows upward into the subcapsular tissue which borders from the right side the main plane of division until the anterior side of RPD. The initial ducts are accompanied by terminal branches of the cystic artery originating from the left branch, while superiorly to the left of the duct an anastomotic arch is stretched that connects caudate lobe artery arising from the right branch and cystic artery originating from the left branch of the hepatic artery Jurkovikj [11].

Figure 4: RPD-medium short arch with convexity being directed downward, and then forward. RAD- shorter, almost straight duct being directed backward to the left and downward. RAD emerges below the level of the middle part of RPD, at a small distance anteriorly. The confluence is at a right angle with the terminal part of LHD, at a short internal distance with an angle open to the right upward, and the terminal part of RAD is anterior and inferior to the same part of RPD (left). Anterior view of cast: UBC, LHD, RPD, RAD and CHD (right).

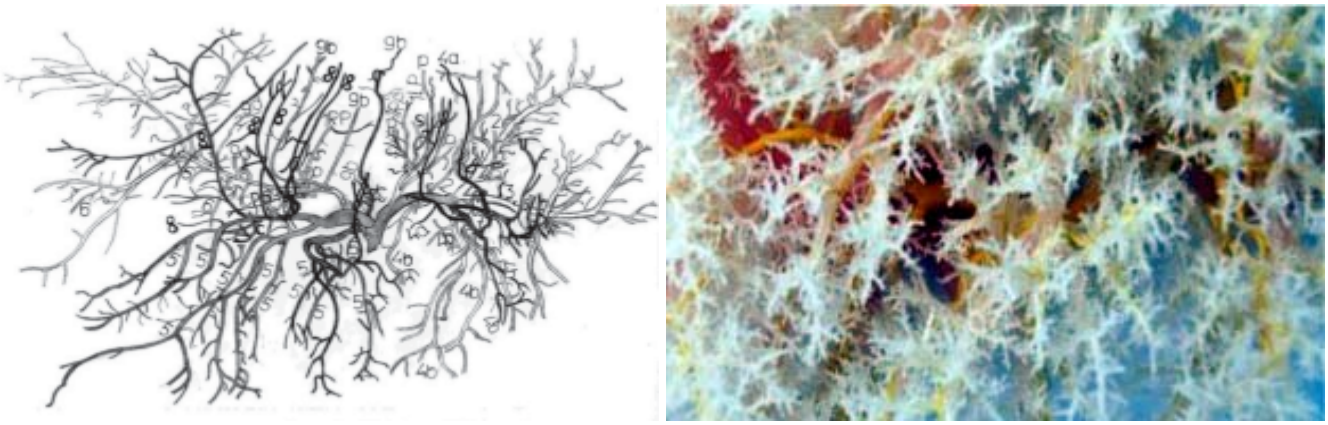

Figure 5: RPD- long sinusoidal duct with convexity being directed downward, and then to the left, upward and backward. STEM-with convexity being directed backward. RHD-arch-like with convexity directed upward, to the left and backward. RPD is above the level of the stem and at a significant distance posteriorly. The confluence is at a right angle with the initial part of RHD, with a significant distance between RPD and the STEM of segmental duct 8 and segmental duct 5, and the angle is open to the right (left). Anterior view of cast: LHD, RHD, STEM of segmental duct 8 and segmental duct 5, and segmental duct 5 (right).

The third case, similar to the previous one, is an accessory subvesical duct (duct of Luschka) from the left side of the vesicular fossa of segment 4b. There is an initial arch which gives rise to a duct directed to the right and forward and upward through the main plane of division. It joins a duct that is a tributary of the segmental duct which finally drains in the anterior right sectorial duct (Fig. 2). Both ducts intraparenchymally accompany portal branches separated from the anterior branch of the portal vein, and they create the right half of the vesicular fossa (segment 5).

In the same case, proximally below the hepatic porta, an accessory duct is seen originating from a subcapsular tissue. It is being directed transversally to the left and upward and superficially crosses a lateral branch of the third order of the portal branch that reaches the visceral surface (segment 5). The described duct enters the right side of the initial part of the cystic duct, which on the other hand, has a high confluence with the initial part to the right side of the common hepatic duct (Fig. 2).

Discussion

Clinical radiological diagnostics, gastroentero-logical and surgical-transplantation practice often encounter findings of variable anatomy and topography of the elements that create the biliary tree. In this respect, substantial is the contribution of a number of esteemed doctors in defining the notions of normal (modal) and accessory or aberrant anatomy. Consensus has been reached for normal biliary anatomy as well as for nomenclature of hepatic anatomy and resections [12].

Couinaud [13] has prepared a catalogue of theoretical variations about the variants of the right hepatic duct. If a duct of Ist order is not formed, then a right duplicated duct is seen. If ducts of IInd order are not formed, then is duplication of the sectorial ducts into two segmental ducts and a separate duct may slide toward other ducts. Quite evidently, the higher the branch order, the more numerous are the varieties.

Similar to Couinaud's classification [14] is the Ohkubo's classification system [15] in which confluence patterns of the right intrahepatic bile ducts were classified into three patterns according to the anatomic relation between the right posterior sectional bile duct and the right or right anterior portal vein: supraportal, infraportal and combined patterns.

Adult living donor liver transplantation using the right lobe is a successful procedure. Postoperative morbidity, mainly caused by biliary leak, was directly related to the number of ducts (a single duct, 2 or 3) and type of anastomosis [16].

In the evaluation of MRC Kim et al. [1] and MRCP Limanond et al. [2] normal, aberrant and undetermined biliary anatomy have been presented. Huang's classification [17] includes: conventional anatomy of right and left hepatic ducts forming a common hepatic duct (type A); trifurcation formed by the right anterior sectorial branch, the right posterior sectorial branch and the left hepatic duct (type B); drainage of the right posterior sectorial branch into the left hepatic duct (type C); drainage of the right posterior sectorial duct into the

common hepatic duct (type D) and drainage of the right posterior sectorial branch into the cystic duct (type E).

According to the terminology given by Daseler et al. [18] variations in the origin of the right hepatic artery are as follows: a normal right hepatic artery is one which supplies the right lobe of the liver, after originating from a normal common hepatic artery; a replacing type of right hepatic artery is one by which the right lobe is supplied from other than the above-mentioned source, and accessory right hepatic arteries supplying the right hepatic lobe, additive to a normal or replacing artery.

Analogous to the previously said, biliary tree branching may have normal anatomy or modal, then aberrant (replacing type) ducts and accessory ducts. If aberration is false, then aberrant ducts would be those with false confluence than the normal one, but only if they constitute the main duct of the relevant structural unit of the liver. Additional to the normal or aberrant duct of one structural unit, there might be one or several ducts that are accessory drainage for that part of the parenchyma.

In Nikolik's systematization [19] only anastomotic small ducts are accessory, whereas the aberrant are those ducts that enter lower than the upper biliary confluence.

Lee et al. [4] for the living liver transplant donor candidates has defined a normal biliary anatomy in 78 cases (72%) and variants of biliary anatomy of the right hepatic lobe in 30 cases (28%) referring to the aberrant posterior right duct as well as existence of accessory right and left ducts.

According to Lee et al. [4] and Lim et al. [20] the biliary anatomy was normal when there was confluence of the right posterior and anterior hepatic ducts to form the right hepatic duct, which joined the left hepatic duct to form the common hepatic duct.

Interpretation of the Results

The analyzed material has shown that the modal type of CHD forming is defined in cases with present right and left hepatic duct. Cases where sectorial right duct did not form right hepatic duct have been defined as of aberrant type. Regardless of the merging pattern, CHD origin is considered to be distal after confluence of both right sectorial ducts since CHD drains both lobes entirely. In correlation with portal morphology, in all cases that did not form RHD a shorter or a longer right branch of the portal vein is observed. This branch is presented with different morphology in its division: 2 cases are with trifurcation in a branch for segment 7, a branch for segment 6 and an anterior sectorial branch; in one case with bifurcation in anterior and posterior branch, where the posterior branch immediately separates a branch for segment 6 and continues into a branch for segment 7, and in the remaining 2 cases the right portal branch bifurcates, but the anterior branch in both cases is more developed than the posterior one, which is very short in one of them.

The site of origin of CHD is in the hepatic porta (hilar confluence [20]) or at a lower extrahepatic level. Forming of CHD at intrahepatic, that is, at intraparenchymatous level has not been observed on the examined material. Its relation with the portal elements is in agreement with the findings of Couinaud [14] and with his statement that UBC is never placed right from the portal trunk if there is no right portal branch.

In the largest number of cases the right hepatic duct is absent, or it is with a short bifurcation form, and rarely with a longer length in comparison with that of the left hepatic duct, which is approximately 1/3 to 1/4 of its length. In the aberrant type of CHD forming, right ducts merge with LHD at an insignificant or short distance. In cases like these of graft for LDLT with a small distance between both right ducts, hepatoplasty is applied with suture of two adjacent walls of the ducts to obtain a unique lumen for biliary anastomosis [16].

Biliary reconstruction in the recipient mainly depends on the morphology of the bile ducts in the graft. If 2 or 3 ducts were present in the graft, but they were close to each other (less than 5 mm apart) reconstruction of the bile ducts was performed at the bench (ductoplasty) to obtain a unique duct for the anastomosis in the recipient. Individuals with a conventional pattern and a RHD longer than 1 cm were candidates for simple duct-to-duct reconstruction. Donors with shorter RHD or any kind of variant were candidates to a more complex procedure: bench ductoplasty or multiple duct anstomoses [21].

According to the pattern of origin, RHD has a modal type in 7 of the 8 cases of its forming. The single case is a rarity of absent RAD, and the segmental ducts of the anterior sector merge in a mixed type until the beginning of RHD. Portal morphology in this case consists of a very short right branch of the portal vein and its division in a poorly developed posterior branch, duplicated anterior branch for segment 5 alone, a small branch for the right dorsal sector-9c and prolongation in

a dominantly developed anterior branch which immediately divides for segments 5 and 8. This case compared with the variants of the right paramedian (anterior) duct described by Couinaud [13] is a combination of scission of the ducts of segments 5 and 8 and an incomplete duplication of RAD for segment 5 alone.

The presented forms of merging of the ducts could be of significant contribution of the anatomic studies to the surgical-diagnostic hepatobiliary practice especially to the imaging techniques and to the interventional procedures as like a performing of percutaneous transhepatic cholangiography (PTC), placement of stent, ductoplasty and drainage of obstructed and dilated ducts.A special accent has to be put on the case of stretching of the right posterior duct below the level of the anterior. Literature and presented classifications report on the lower level of confluence of RPD than of UBC [1-4, 13, 15], but this case can be compared with the type D of the infraportal pattern of Ohkubo et al. [15] and this is a case of usual merging of this duct with the anterior sectorial duct forming RHD in the porta hepatis.

The examined material showed no cases of trifurcation of the right sectorial ducts with LHD versus cases of a separate confluence of RPD into LHD followed by confluence of RAD distal to it. Cases like these are very often a subject of false or disputable interpretation of MR image i.e. require additional investigations and clarification from possible trifurcation [1, 2, 20] or normal biliary anatomy [4]. If accompanied with inflow of segmental branches of the right biliary tree in the hepatic confluence, they may be contraindicated for obtaining right lobe liver transplant [21].

According to the drainage area, accessory ducts are profound (from the parenchyma itself), subvesical (from the tissue that surrounds the site of the gallbladder and gallbladder itself) and subcapsular (from the tissue between the capsule and the parenchyma).

Literature data reveal that bile ducts emerge from the hilus or from the inferior side of the liver [22], that is, from the parenchyma [19]. For the first time aberrant ducts that leave the liver were described by Ferrein in 1733 [23], and later by Kiernan in 1833 [24]. However, an old finding is that colored dye such as methillen blue if injected through the hepatic duct, in a few minutes it leaks to the surface in a model of spots and patches. Except subvesical duct, ducts in the connective tissue have also been described in which inferior vena cava is submerged, in the extraperitoneal fat between the layers of the falciform ligament, also in the tissue in the fissure for the round ligament and the saccus, as well as between the layers of the left triangular ligament until the diaphragm, the latter being associated with portal and arterial branches (intrahepatic processuses) [25].

Comparable with the modalities of the vascular area of the cystic artery [18], the presented accessory ducts have confirmed an associated biliary drainage from both halves of the vesicular fossa (subvesical) toward the right biliary system along partial drainage of segment 5 from the part that reaches the visceral surface through CHD.The significance of these vasculobiliary elements from the point of view of many clinical disciplines (infectology, microbiology, haematology, transfusiology) is connected with causes of liver diseases accompanied with portal and primary or secondary biliary cirrhosis and liver damage.

Similar to the accessory duct, a tributary of the cystic duct, Ohkubo et al. [15] described a dorsal subsegmental branch of the right anterior inferior bile duct joined with the cystic duct.

Schroeder et al. [26] visualized the biliary tree to the third even to the fourth level of intrahepatic branches and drainage of a small duct from liver segment four into the RHD and both an additional right and left hepatic duct draining into the CHD.

According to Bak et al. [27] accessory posterior right-lobe bile ducts draining to the left hepatic duct are identified. Small accessory bile ducts (<3 mm), particularly those in a very posterior position that would be technically difficult to reconstruct, are overseen.

On the analyzed material, except in the accessory ducts, crossing of the main plane of division has also been noticed in 2 of the 4 cases of consequent drainage of RPD into LHD, but the duct that crosses the plane is LHD that passes to the right. In the remaining 2 cases, 3 ducts are at the level of the main plane of division - RPD, RAD and LHD, but in one of them in front of the left, and in the other in front of the right branch of the portal vein. The location of these biliary elements is important from the aspect of the plan for parenchymal transection in right hepatectomy, which is adjacent to the right border of Cantlie's line [9].

This study is directed only to the common and right hepatic ducts because we have previously investigated and published our findings about the modal type Jurkovikj and Korneti-Pekevska [28] and important biliary drainage variations of the left lateral liver section Jurkovikj [29].

Conclusion

Common hepatic duct has shown modal and aberrant type of forming at the level of the hilum or at a lower extrahepatic level.

The right hepatic duct might be absent; it might be with a very short bifurcation form, and rarely with a significant length. It usually shows a modal type of forming, and on exception, aberrations associated with portal morphology. Of the right sectorial ducts, the trunk of the posterior duct is usually longer than the anterior one, and rarely they have approximately same relative length. Usually the anterior duct is lower and in a more anterior position than the posterior duct, except in one case of infraportal location of the posterior duct in comparison with anterior branch of the portal vein. In aberrant confluence of the posterior, and then anterior duct into the left hepatic duct, the anterior duct might be insignificantly posteriorly or anteriorly.

Accessory ducts are arising deeply from the parenchyma or supraparenchymally in the subvesical or subcapsular connective tissue. Their drainage is associated with accompanying arterial vascularization from the cystic artery, dorsal branches for segment 5 and arterial arcades for caudate process.

References

1. Kim DR, Sakamoto S, Haider AM et al. Role of magnetic resonance cholangiography in assessing biliary anatomy in right lobe living donors. Transplantation. 2005;79(10):1417-21.

2. Limanond P, Raman SS, Ghobrial RM, Busuttil WR, Lu SKD. The utility of MRCP in preoperative mapping of biliary anatomy in adult-to-adult living related liver transplant donors. J Magn Reson Imaging. 2004;19:209-15.

3. Ayuso RJ, Ayuso C, Bombuy E et al. Preoperative evaluation of biliary anatomy in adult live liver donors with volumetric mangafodipir trisodium enhanced magnetic resonance cholangiography. Liver Transpl. 2004;10(11):1391-7.

4. Lee SV, Krinsky AG, Nazzaro AC et al. Defining intrahepatic biliary anatomy in living liver transplant donor candidates at mangafodipir trisodium-enhanced MR cholangiography versus conventional T2-weighted MR cholangiography. Radiology. 2004;233:659-66.

5. Taourel P, Bret MP, Reinhold C, Barkun NA, Atri M. Anatomic variants of the biliary tree: diagnosis with MR cholangiopancreatography. Radiology. 1996;199:521-7.

6. Irie H, Honda H, Tajima T, Kuroiwa T, Yoshimitsu K, Makisumi K, Masuda K. Optimal MR cholangiopancreatographic sequence and its clinical application. Radiology. 1998;206:379-87.

7. Fulcher SA, Turner AM, Capps WG, Zfass MA, Baker MK. Half-fourier rare MR cholangiopancreatography: experience in 300 subjects. Radiology. 1998;207:21-32.

8. Broelsch ECh, Malago M, Testa G, Gamazo VC. Living donor liver transplantation in adults: outcome in Europe. Liver Transpl. 2000;6(6)Suppl 2:S64-S65.

9. Miller MCh, Gondolesi EG, Florman S et al. One hundred nine living donor liver transplants in adults and children: a single-center experience. Ann Surg. 2001;234 (3):301-12.

10. Jurkovikj MD. Hepatic arterial anatomy with survey of the cases with congenital arterial anastomosis. Acta Morphol. 2006;3(2):7-18.

11. Jurkovikj MD. The biliary drainage of the liver-a case report of an accessory bile duct. Mak Med Pregled. 2002:1-2: 76-9. [Macedonian]

12. Strasberg MS. Nomenclature of hepatic anatomy and resection: a review of the Brisbane 2000 system. J Hepatobiliary Pancreat Surg. 2005;12:351-5.

13. Couinaud C. Tell me more about liver anatomy. Paris: Karger, 1999:p. IX, 6, 72.

14. Couinaud C. Surgical anatomy of the liver revisited. Pers. Ed. Paris; 15, rue Spontini, F 75116, 1989:p. 112.

15. Ohkubo M, Nagino M, Kamiya J et al. Surgical anatomy of the bile ducts at the hepatic hilum as applied to living donor liver transplantation. Ann Surg. 2004;239(1):82-6.

16. Testa G, Malago M, Gamazo VC, Lindell G, Broelsch ECh. Biliary anastomosis in living related liver transplantation using the right liver lobe: techniques and complications. Liver Traspl. 2000;6(6):710-4.

17. Huang TL, Cheng YF, Chen CL et al. Variants of the bile ducts: clinical application in the potential donor of living-related hepatic transplantation. In: Kim DR, Sakamoto S, Haider AM et al. Role of magnetic resonance cholangiography in assessing biliary anatomy in right lobe living donors. Transplantation. 2005;79(10):1417-21.

18. Daseler HE, Anson JB, Hambley CW, Reimann FA. The cystic artery and constituents of the hepatic pedicle. A study of 500 specimens. Surg Gyn Obst. 1947;85(17):47-63.

19. Nikolik V. Aberantni ekstrahepatalni zhuchni vodovi. Rad Med fak u Zagrebu. 1966;14:179-92.

20. Lim SJ, Kim MJ, Kim HJ et al. Preoperative MRI of potential living-donor-related liver transplantation using a single dose of gadobenate dimeglumine. AJR. 2005;185:424-31.

21. Liu LCh, Lo MCh, Chan ChS, Tso KW, Fan TSh. The right may not be always right: biliary anatomy contraindicated right lobe live donor liver transplantation. Liver Transpl. 2004; (6):811-2.

22. Radojevik S. Akcesorni zhuchni putevi u anatomskom I hirurshkom pogledu. Srp arhiv. 1930;32:836-43

23. Ferrein. 1733. Cited in: Hobsley M. intra-hepatic anatomy. A surgical evaluation. Brit J Surg. 1958;45:635-44.

24. Kiernan F. 1833. Cited in: Hobsley M. intra-hepatic anatomy. A surgical evaluation. Brit J Surg. 1958;45:635-44.

25. Hobsley M. intra-hepatic anatomy. A surgical evaluation. Brit J Surg. 1958;45:635-44.

26. Schroeder T, Malago M, Debatin FJ, Testa G, Nadalin S, Broelsch ECh, Ruehm GS. Multidetector computed tomographic cholangiography in the evaluation of potential living liver donors. Transplantation. 2002;73(12):1972-4.

27. Bak T, Wachs M, Trotter J et al. Adult-to-adult living donor liver transplantation using right-lobe grafts: results and lessons learned from a single center experience. Liver Transpl. 2001;7(8):680-6.

28. Jurkovikj MD, Korneti-Pekevska K.Left lateral liver section (Anatomo-surgical aspects of modal type of porto-biliary elements). Mak Med Pregled. 2009;63(3);39-47.

29. Jurkovikj D. Important biliary drainage variations of left liver lobe. Prilozi. 2009;30(2):81-92.