

Nutritive Support in the Control of Nutritive Status in Acute Corrosive Poisonings: A Case Report

Andon Chibishev

University Clinic of Toxicology, Faculty of Medicine, University "Ss Cyril and Methodius", Skopje, Republic of Macedonia

Abstract

Citation: Chibishev A. Nutritive Support in the Control of Nutritive Status in Acute Corrosive Poisonings: A Case Report. *Maced J Med Sci.* 2010 Dec 15; 3(4):395-399. doi:10.3889/MJMS.1957-5773.2010.0123.

Key words: Corrosive poisonings; esophageal burns; esophagogastroduodenoscopy; enteral nutrition; parenteral nutrition.

Correspondence: Chibishev Andon, MD. University Clinic for Toxicology, Vodnjanska 17, 1000 Skopje, Republic of Macedonia. Tel: +389 2 3211 072; +389 70 387 040; +389 75 223 223. E-mail: vesnubrat@yahoo.com, toksikourgentna@gmail.com

Received: 14-May-2010; Revised: 04-Jul-2010; Accepted: 22-Jul-2010; Online first: 12-Oct-2010

Copyright: © 2010 Chibishev A. This is an open-access article distributed under the terms of the Creative Commons Attribution License, which permits unrestricted use, distribution, and reproduction in any medium, provided the original author and source are credited.

Competing Interests: The author have declared that no competing interests exist.

Acute poisonings with corrosive substances are one of the most difficult poisonings in the clinical toxicology. Here we present a case of a woman who survived poisoning with hydrochloric acid, and in the course of five months she was given artificial enteral nutrition through a feeding gastro-jejunostoma.

In the first 24 hours after hospitalization, an emergency esophagogastroduodenoscopy was done and corrosive damages were observed along the esophagus, in the stomach and partially in the duodenum that bled temporarily. Postcorrosive burns of the esophagus and stomach of grade III according to Kikendal' classification were confirmed and bleeding from the mucous membrane, submucosis and muscle layer.

The intensive worsening of the general condition because of the stress and acute hunger, indicated that feeding gastro-jejunostoma should be inserted after the fifth day of hospitalization when an abdominal surgeon was consulted. During her stay in the hospital, nutritive status of the patient was monitored (body weight, body mass index, total proteins, albumins, nitrogen loss, nitrogen balance).

The intensive hyper-alimentation improved the general condition and it stabilized the laboratory, metabolic and immunology parameters. After six months of home enteral nutrition, a partial resection of the distal part of esophagus and total gastrectomy were indicated because the patient had definite post-corrosive sequels.

Introduction

Injuries caused by corrosive means poisoning are as old as the chemicals themselves. Contemporary technology enables synthesizing of corrosive means which have widespread usage in industry, households and everyday life.

Poisoning with corrosive means, according to the way of taking, can be: - per oral (taken through the mouth); - per inhalation (inhaled); - contact (by direct contact with the skin or contact of the corrosive

agent with the eyes) [1].

According to the motive, the poisoning can be: - suicidal, which is more frequent, and - accidental, which is rarer.

Swallowing of the corrosive means is manifested by weakly or more intensively expressed corrosive effect on the saliva (mucosa), submucosa and muscle layer of the esophagus, stomach and duodenum. The most severe damages appear in the esophagus and in the stomach because the substrate stays there most of

the time [2]. Extensive damages of the gastrointestinal tract disable the physiologic nutrition in these patients. For a short period of time they are in a very difficult general condition either because of hyper catabolic condition or negative nitrogen balance. Therefore, the early enteral and parenteral nutritive support plays an important role in the treatment of these patients [3].

Enteral and parenteral nutrition enable life-saving therapy for patients who can not take food and because of that they are in a risk of malnutrition.

The effects of enteral and parenteral nutrition of patients intoxicated with corrosive means are: - decreasing the possibility of infections; - decreasing the predisposition to appearance of aspiration pneumonia; - decreasing the risk concerning pulmonary embolism; - economic effect [4].

Acute poisonings with corrosive means are one of the most difficult poisonings in the clinical toxicology. Here we present a case of a woman who survived poisoning with hydrochloric acid, and in the course of six months she was fed artificially enteral through a Feeding gastro-jejunosoma.

The aim of this work is to show the possibility for nutrition in a critically ill patient in a way which is more natural to the physiologic one and its control by standard clinical and biochemical examinations.

Case Report

A female patient on the age of 37, with suicidal intentions, drank a greater quantity of hydrochloric acid. The anamnesis and hetero-anamnesis revealed bad family relations for a longer period of time, so the patient also had previous suicidal trials. The patient, after a bitter family conflict and in a depressive condition, drank approximately 10-20 ml of hydrochloric acid.

She was immediately transferred to the local medical center. Having been given a certain therapy she was transferred and hospitalized at the University Clinic of Toxicology.

When received at the Clinic she complained of pains and scorch in her mouth, throat, chest, and stomach, disgusting, vomiting of bloody content, weakness and exhaustion.

A physical examination was also made and the following parameters were determined: the patient was conscious, contact responsive, oriented in time and

space, recognized persons, dyspneic, the artery pressure was 100/60 mm Hg, eucardiac, pulse was 80 per minute. The electro cardiographic finding after the admission was in normal limits.

Urgent esophagogastroduodenoscopy was done in the first 24 hours, when severe post corrosive damages were stated along the esophagus, in the stomach and in the part of duodenum which bled temporarily. Post corrosive burns of the esophagus and stomach were confirmed (III-rd degree according to Kikendal and bleeding from the mucous membrane, submucosis and muscle layer (Forest II).

The intensive worsening of the general condition, because of the stress and acute hunger, indicated that Feeding gastro jejunosoma should be implanted after the fifth day of hospitalization when an abdominal surgeon was consulted. In the further course of hospitalization, the patient was fed enterally and supplementary parenterally.

The intensive hyper alimentation made the general condition better and it stabilized the laboratory, metabolic and immunology parameters.

Permanent following of the body weight and laboratory parameters that defined the relations of the nutritive status was checked on admission of the patient, on the seventh day, on the fourteenth day and after dis-

Table 1: Laboratory findings at the admission day, during the nutritive support and at the dismissal of the patient who survived poisoning with hydrochloric acid.

	Admission	7 th day	14 th day	Dismissal	Normal Values
Body weight (kg)	49	47	49	50.5	-
BMI (body mass index kg/m ²)	20	19	20	20	-
SE	28	24	18	15	4-10
Hemoglobin	108	104	112	115	m. 140-180; f. 120-160
Red blood cells Erc (10 ¹² /L)	4.0	3.8	4.2	4.3	4.2-5.5
Hematocrit	0.28	0.29	0.38	0.39	0.37-0.54
Glucose (mmol/L)	4.8	4.2	4.1	3.9	3.5-6.5
Urea (mmol/l)	2.1	4.4	4.9	5.1	3.0-7.8
Creatinine (mmol/L)	53	80	79	70	45-109
Urine acid (mmol/L)	177	200	276	189	150-450
Nitrogen loss (g/N)	14.61	13.71	12.65	13.21	-
Nitrogen balance (150:1g N)	150:1	145:1	158:1	151:1	150:1g N
Na (mmol/L)	141	144	139	141	135-145
K (mmol/L)	3.4	3.5	4.1	4.0	3.8-5.5
Ca (mmol/L)	2.1	2.0	2.1	2.3	2.2-2.7
Fe (μmol/L)	5.5	5.1	5.8	6.1	m. 11-28; f. 7-26
TIBC (μmol/L)	54	54.5	54.4	55	46-70
Transferrin (g/L)	0.2	0.6	0.52	1.0	2.0-3.6
Alkaline phosphatase (U/L)	87	131	137	73	11-85
AST (U/L)	26	41	34	22	4-34
ALT (U/L)	14	30	28	31	3-45
CPK (U/L)	102	144	88	40	<70
LDH (U/L)	161	324	108	88	120-240
Total proteins (g/l)	60	48	61	66	65-80
Albumins (g/l)	32	27	32	39	35-50
Globulins (g/l)	28	21	28	27	27-35
Total bilirubin (μmol/L)	6	13	12	16	6.8-20.5
Direct bilirubin (μmol/L)	3	6	8	6	1.5-6.8
Indirect bilirubin (μmol/L)	3	4	4	6	5.1-13.6
Total bilirubin (μmol/L)	6	13	12	16	6.8-20.5
Direct bilirubin (μmol/L)	3	6	8	6	1.5-6.8
Indirect bilirubin (μmol/L)	3	4	4	6	5.1-13.6

missal from the hospital. The results showed referent maintenance of patient's nutritive status during the whole period of hospitalization (Table 1).

The patient was treated by standard nutritive liquids, for parenteral and enteral nutrition, that were available at the market at the moment of hospitalization, namely antibiotics, antacids, H₂ blockaders, polyvitamin

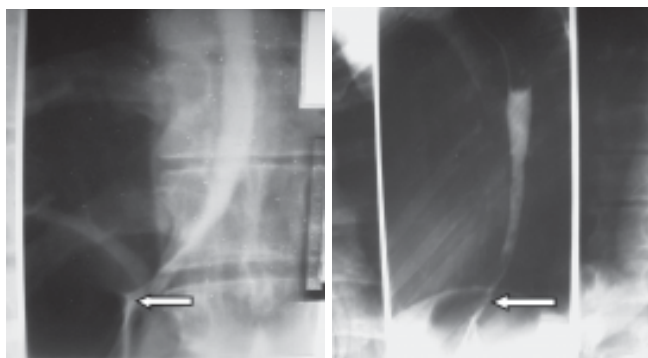


Figure 1: Stenosis of the lower part of esophagus.

and symptomatic therapy. The control endoscopy after 15 and after 30 days, and X-rays investigations after 30 days of hospitalization showed stenosis on the esophagus and pylorus (Fig. 1, 2).

These findings indicated the need that the nutritive substitute through Feeding gastro jejunostoma should

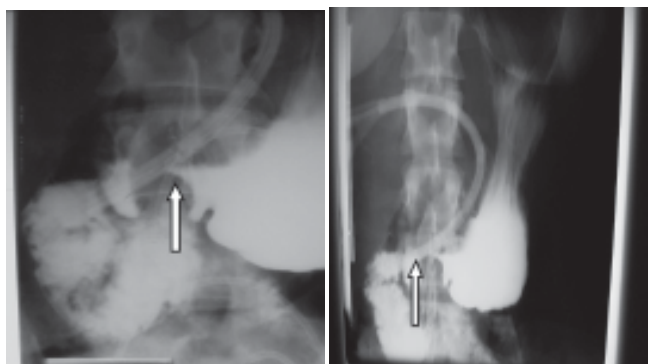


Figure 2: Stenosis of pylorus.

continue in future. The patient was dismissed for home care and enteral nutrition in home conditions (home enteral nutrition). Home enteral nutrition was maintained in collaboration with the family of the patient, who were given appropriate instructions.

After five months of home enteral nutrition, the patient was indicated a partial resection of the distal part of esophagus and total gastrectomy because of definite post corrosive sequels.

Discussion

Today, the incidence of acute corrosive poisonings increases.

The American Association of Centers for Poison Control published data about 22.000 acid poisonings, 50.500 bases poisonings, 16.272 peroxide poisonings, 54.300 bleaching liquids poisonings, and 2.322 poisonings by phenols or phenol substances per year [5].

Important is the fact that the acute per oral corrosive poisonings participate with 8 - 10% in the total number of poisonings, with 40 - 80% in the complications, and 20 - 38% in the mortality [6].

Severe damages of the upper part of gastrointestinal tract, with patients intoxicated by corrosive means, make physiological nutrition very difficult and impose the need of alternative nutrition [7].

Deskin R. [8] recommends the so called "esophageal rest" with patients having acute corrosive poisonings. It will be enabled if the patient does not feed oneself through the mouth (NPO or nil per os). During the "rest" the patient is fed with nasoenteral tube, gastrostoma or jejunostoma. He explains it with the fact that the food particles go into the granulocytes of the esophageal wall and worsen the inflammation. In case of impossibility for enteral nutrition TPN (total parenteral nutrition) is recommended.

Kikendal [9] recommends that the esophageal "rest" should last at least 10 days after the set endoscopic diagnosis concerning the poisoning.

Eric Kardon [10] does not recommend nutrition through the mouth (NPO) in acute poisonings with corrosive means up to the first endoscopic control (between 15th and 20th day).

Although some authors suggest taking of smaller or grater quantity of liquids and liquid food through the mouth, the nutritive needs are mainly satisfied by total parenteral and/or enteral nutrition through Feeding gastrostoma or jejunostoma [11].

Main indications for enteral nutrition are: - poor nutritive status; - insufficient food taking; - dissatisfactory nutrition; - malnutrition; - anorexia; and - impossibility for oral ingestion of suitable nutrients in functional GIT.

The basic advantages of enteral nutrition are: - simpler and safer for application and following; - its role is more physiologic (maintenance of the functional intes-

tine mucositis, decreased possibility of bacteria translocation, proved nutritive utilization, decreased number of hepatobiliary complications); - it is cheaper (economic effect).

Enteral nutrition has great benefit in critically ill patients who, at the same time, show lower percentage of life-dangerous infections: - abdominal abscesses, pneumonia, bacteriemia; - decreased number of ventilation complications; - shorter stay at the hospital; - decreased mortality; - decreased number of fatal complications connected to the central vein catheter (embolism).

The possibility of more efficient energetic consumption, the control of metabolic processes, the possibility of more efficient water-electrolyte and biologic monitoring, the decreased danger of liquids and sodium over administration by appearance of edema, and the decreased number of lungs complications give an advantage to enteral nutrition concerning the choice of nutritive substitute [12].

The results of our examinations showed a decrease of the body weight in the first 14 days after caustic ingestion and admission to hospital. However, this decrease was not over 5% of the usual body weight, which is in agreement with the defined criteria. Our results are based on the ratio current-ideal body weight that is assumed to be a bad indicator since very rarely patients have ideal body weight prior to disease onset. Our patient was hospitalized and given artificial support without previous evident disease that would lead eventually to a disorder of both the body weight and body mass index. According to the criteria established and published by ESPEN in the third edition of Basics in Clinical Nutrition, our patient had a mild body weight loss in the first 7, that is, 14 days, followed by a stable, maintained and mild increase of the actual body weight [13].

Monitoring of the enzyme status is of major importance because of the devastating destructive and necrotizing changes caused by corrosive poisonings. Observation of the hepatic function is also important since it is compromised due to non-physiologic nutrition and application of nutritional solutions containing fats. Our results have shown that there was no renal function disorder resulting from the artificial support and administration of lipid solutions [14].

Sax HC and Hardy DJ [15] followed-up a group of patients receiving nutritional support. They concluded that there was an increased concentration of hepatic

enzymes and bilirubin in some of the patients; in others there was a change in the morphology of the hepatocytes and in some of the patients hepatic damages were so severe that one patient died from the complications. The authors explained this outcome as a consequence of a large concentration of toxins, administration of inadequate substrates, overdosage with nutritional solutions, insufficient and inappropriate feeding and change in the intestinal enzymes.

Nitrogen balance represents a difference between intake and elimination of nitrogen and it is an essential parameter for assessment of protein needs. Measurement of nitrogen excretion is a reliable parameter for assessment of protein metabolism and also evaluation of efficiency of protein utilization. Knowledge about nitrogen elimination is particularly important for the treatment of critically ill patients, who are under a major stress and whose visceral and somatic metabolism might be influenced by optimizing the nutritive nitrogen dose, thus creating conditions for improvement of the anabolism [16].

Poly-traumatized patients have a negative nitrogen balance and muscle loss. In these patients, the standard nutrition is insufficient because it cannot enhance the loss of that protein part originating from the muscles. A double study conducted on 12 patients showed that continual infusion with L-leucin and administration of specific solutions containing cysteine, threonine, serine and alanine contributed to maintenance of nitrogen balance in critically ill patients [17].

Stabilization and improving of the laboratory and metabolic parameters, as well as the prevention of intestines malfunction and bacteria translocation give advantage to enteral nutrition and its administration with life-threatening patients, especially in those having functional GIT, but insufficient nutritive status [18].

Since it is possible the enteral nutrition to be practiced in home conditions and the hospital expenses are significantly decreased (economic effect), a lot of Centers in the world prefer the so-called home enteral nutrition. Even special professional teams are trained for this purpose [19].

Conclusion

Corrosive poisonings are ones of the most difficult poisonings in the clinical toxicology because of the severe destructive chemical injuries of the upper part of

gastrointestinal tract. They represent a serious medical and social problem from the aspect of clinical presentation, clinical picture, clinical investigations and the therapeutic approach, so the therapy and results are often uncertain.

Because of the impossibility for physiologic nutrition, alternative ways of feeding for the first 10 to 15 days are sought, while the process of inflammation, vascular thrombosis and granulation is still lasting.

This report shows that the early enteral nutrition through enterostoma enables physiologic nutrition of patients having post corrosive damages of the upper part of gastrointestinal tract and maintenance of the nutritive status in referential values.

References

1. Andreoni B, Biffi R, Padalino P, Marini A, Marzona L, Belloli S, Farina ML, Tiberio G. Artificial nutrition in the management of lesions caused by caustic ingestion. *Chir Ital.* 1994;46(6):42-8.
2. Christessen HB. Ingestion of treatment caustic agents, Epidemiology. Pathogenesis, course, complications and prognosis, *Ugskr Laeger.* 1993;155(31):2379-2382.
3. Munoz Botero NA, Perez Lano AM, Rodrigez Herrera et al. Nutrition therapy for adult patients with caustic injuries to gastrointestinal tract. *Nutr Hosp.* 2010; 25 (2):231-237.
4. Berthet B, Bernardini D, Lonjon T. Treatment of caustic stenoses of the upper digestive tract. *Chir (Paris).* 1995;132(11):447-50.
5. Christessen HB. Diagnostic and treatment of caustic ingestion. *Ugskr Laeger.* 1994;156(28):4125-4126.
6. Bozinovska C. Xenotic changes in acute corrosive intoxications. *Archives of Toxicology, Kinetics and Xenobiotic Metabolism.* 1998; 3:115-7
7. Chibishev A, Chibisheva B, Bozinovska C, Naumovski J et al, Oesophageal and gastric stenoses are common complications after acute oral poisoning with corrosive agents. *Maced J Med.* 2005;51(1-2):139-146.
8. Deskin R. Caustic Ingestion, Dept. of Otolaryngology, U TMB, Grand Rounds; 1995 Available from: www.utmb.edu/otoref/grnd/Aerodigestive-Tract-2001-04.htm
9. Kikendal JW. Caustic ingestion injuries. *Gastroenterol Clin North Am.* 1991;20(4):847-857.
10. Kardon E. Toxicity caustic ingestion. *Medicine*, July 2004 Available from: emedicine.medscape.com Emergency Medicine Toxicology. Accessed Dec 2009.
11. Alinejad A. Caustic injury to upper gastrointestinal tract. com [homepage on the Internet]. Shiraz university of medical sciences, Department of Internal Medicine, 2000 [updated 2000; cited June 2010]. Available from: pearl.sums.ac.ir/semj/vol4/jan2003/causticinj.htm
12. Mansoor O, Breuille D, Becheriau F et al, Effect of enteral diet supplemented with a specific blend of amino acid on plasma and muscle protein synthesis in ICU patients. *Clinical Nutrition.* 2007;26:30-40.
13. Basics in Clinical nutrition. Edited for ESPEN. Third Edition. Editor in Chief Lubos Sobotka. 2004;11-34.
14. Sax HC, Bower RH. Hepatic complications of total parenteral nutrition. *J Parenteral Enteral Nutr.* 1998;12(6):615-618.
15. Boehm KM, Helms RA. Assessing the validity of adjusted urinary urea nitrogen as an estimate of total urinary nitrogen in three pediatric populations. *JPEN.* 1994;18(2):172-176.
16. Baxter JP, McKee RF. The Scottish home parenteral nutrition managed clinical network: one year on. *Clin Nutr.* 2003;22(5):501-4.
17. Fletcher JP, Little JM, Guest PK. A comparison of serum transferrin and serum prealbumin nutritional parameters. *J Parent Nutr.* 1987;11:144-8.
18. Chibishev A, Chibisheva B, Bozinovska C, Petrovski D. The importance of parenteral nutrition of postcorrosive complications in acute corrosive poisoning. *Maced Med Pregled.* 2003;57(5-6):278-282.
19. Hobuterne X, Moreno M, Villares M, Pertkiewitz J. Home enteral nutrition in adults, a European multicentre survey. *Clin Nutr.* 2003;22(3):261-266.