***Maced J Med Sci* electronic publication ahead of print,**
published on August 18, 2009 as doi:10.3889/MJMS.1857-5773.2009.0062

Macedonian Journal of Medical Sciences. 2009 Sep 15; 2(3):XX-XX.
doi:10.3889/MJMS.1857-5773.2009.0062
Basic Science

OPEN ACCESS

Lumbar Spinal Stenosis in Older Adults - Gender Differences

Niki Matveeva[1], Miodrag Vrchakovski[2]

[1]Institute of Anatomy, Faculty of Medicine, University "Ss Kiril and Metodij", Skopje, Republic of Macedonia; [2]Institute of Radiology, Faculty of Medicine, University "Ss Kiril and Metodij", Skopje, Republic of Macedonia

Key words:
Magnetic resonance imaging; spine; spinal stenosis; older adults.

Correspondence:
Niki Matveeva, MD
Institute of Anatomy, Faculty of Medicine, University " Ss Kiril and Metodij", Skopje, Republic of Macedonia
E-mail: nikimatveeva@gmail.com

Received: 26-Feb-2009
Revised: 30-Jul-2009
Accepted: 31-Jul-2009
Online first: 18-Aug-2009

Abstract

Background. Spinal stenosis usually occurs in older adults. The treatment of this condition is with varying success It is necessary to assess the risk and the expected benefits of the treatment (surgical or not surgical) in the rapidly growing old segment of population.

Aim. The aim of this study is to present the anatomic and segmental distribution of spinal stenotic changes in the symptomatic old adult males and females and to contribute toward framing an agenda for an optional treatment of this condition in the old segment of the population.

Material and Methods. In the study the anatomic presence of spinal stenotic changes in the symptomatic older adults, referred for lumbar MRI was evaluated. The segmental distribution of spinal stenosis in old adult males and females, if the anatomical unit is the vertebral body and the disc bellow it was presented.

Results. Of the 27 male and female patients with spinal stenosis, 65 and older, according to the localization of the spinal stenosis, the most frequent affected levels were L4 and L3. In the old adult female patients stenotic changes affected more proximal levels of the lumbar spine and there was a significantly larger number of female patients with stenotic changes on two,three and even four adjacent levels.

Conclusion. Spinal stenosis in older adults is multilevel and multifactorial disorder, caused by different factors related to the degenerative processes.

Introduction

Spinal stenosis is abnormal narrowing or constriction of the vertebral canal and/or neural foramina which produces compression of the contents of the canal, paticulary the neural elements. The canal is described as narrow, but not stenotic if the compression does not occur (1). Degenerative spinal stenosis is an acquired condition due to the natural process of spinal degeneration that occurs with aging. This condition is always progressing, gradually worsening over time as a slow or faster degenerative process over a prolonged or short period of time. Degenerative changes and narrowing can occur centrally and in the lateral parts of the vertebral canal (in the lateral recess and in the zone of neural foramina), or as a combination of the two (2). Modern imaging techniques provide visualization of the soft tissue structures that reduce the space of the canal so the measurements of the bony canal are not of great importance. The diagnosis of spinal stenosis is established when the clinical symtomatology (neurogenic claudication, bowel and bladder dysfunction, motor weakness, hyperreflexia and muscular atrophy) is confirmed with the anatomic demonstration of stenosis on MRI (Magnetic Resonance Imaging) or CT (Computerized Tomography).

The old population is also characterized with altered pain tolerance and presence of various endocrinological, cardiovascular, or pulmonary comorbid conditions (3). Better treatment results have been reported in patients randomized to surgical treatment than those receiveing conservative treatment (4). The use of wide decompressive surgical procedures not regarding the integrity of the laminae and facet joints may lead to functional failure of the spine. Surgical decompression should also achieve an adequate level of obtaining good results. When assessing the old patients for treatment of lumbar spinal stenosis, the factors that are taken into consideration are symptoms, age of the patient, health status and comorbidities.

The aim of this study is to investigate are gender differences also an important factor to asses the risk in each optional treatment versus the expected benefit. Therefore, we investigated the anatomic localization or segmental distribution of the lumbar spinal stenotic changes in old female and male adults.

Patients and Methods

This study prospectively analyzed 27 patients, 13 males and 14 females, 65 years and older referred to MRI examination of the lumbar spine with symptoms of neurogenic claudication. Patients who had symptoms of nerve root compression without symptoms of claudication and patients with severe lumbar kyphosis were not included in the study. The diagnosis of spinal stenosis is confirmed only by the anatomic presence of stenotic condition.

All of the MRI examinations of the lumbar spine were performed by using a 1.0-T MR unit (Gyroscan 10 NT) and a dedicated receive-only spine coil. The imaging protocol consisted of a sagittal T1-weighted spin-echo sequence (repetition time msec/echo time msec, 700/12; section thickness, 4 mm; intersection gap, 0.8 mm; field of view, 300 mm; matrix, 512 x 512; number of acquisitions, four), a sagittal T2-weighted turbo spin-echo sequence (5000/130; section thickness, 4 mm; intersection gap, 0.8 mm; echo train length, 15; number of acquisitions, four), and a transverse T2-weighted turbo spin-echo sequence (4000/96; section thickness, 4 mm; intersection gap, 0.8 mm; echo train length, seven; field of view, 150 mm; matrix 256 x 256; number of acquisitions, two). The obtained MR images were assessed in consensus by two radiologists. All of the patients had neuroradiologically confirmed lumbar spinal stenosis.The concomitant diagnosis causing spinal stenosis was lumbar spondylosis in 17 patients and degenerative spondylolisthesis

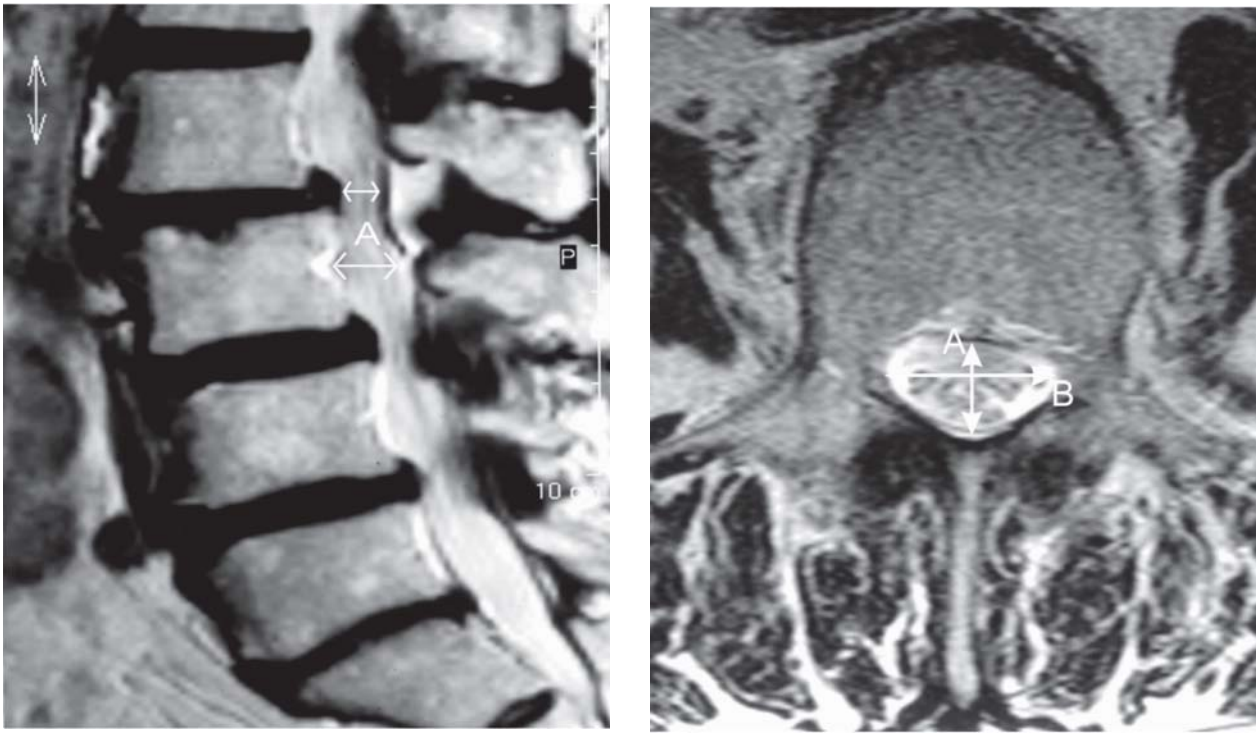

Figure 1: Sagittal and axial T2 weighted MR image of the lumbar spine showing sagittal spinal canal diameter (A), and antero-posterior (A) and transverse dimensions (B) that are used for calculating the cross sectional area of the spinal canal (Yukawa et al., 2002 (5)).

(> 5 mm in sagittal plane) in 10 patients (7 females and 3 males).

The sagittal diameters-(A) of the spinal canal at the mid-pedicle and mid-disc levels were measured from L1 to S1, on T2-weighted sagittal images. The anterior and posterior border of the cerebrospinal fluid column were taken to be the anterior and posterior border of the spinal canal. On T2 weighted sagittal images the cerebrospinal fluid column is delineated from the other structures and the epidural space is very narrow, so the fluid column is used as a reference for measuring the bony canal. The interpedicular distance- (B) was measured on transverse T2 weighted images at the mid-pedicle level from L1 to L5.The measurements of the cross-sectional area were calculated (A X B) at the mid-pedicle level of each anatomical segment (a vertebral body and the disc bellow it) with stenosis by measuring the antero-posterior (A) and transverse dimensions (B) in millimeters (5) (Fig.1).

The level or levels at which the sagittal diameter of the spinal canal was less than 10 mm and the cross-sectional area of the canal was < 100mm^2 were taken as stenotic levels. On MRI of the lumbar spine, the affected level or levels and the number of the affected levels with spinal stenosis were evaluated. The presence of foraminal stenosis was qualitatively assessed.

The anatomic localization and segmental distribution of spinal stenotic changes were analyzed according to the gender of the older adult patients. Statistical analysis of the segmental distribution of the spinal stenotic changes in old adult male and female patients was done by Mann-Whitney U test.

Results

The anatomic presence of stenotic condition on MRI was neuroradiologically confirmed by experienced neuroradiologist in each patient.

Each patient had a combination of central and subarticular stenosis (in the lateral recesses). Eighteen patients of them had stenotic changes in the foraminal zone, too.

Gender differences concerning presence of central, subarticular and foraminal stenosis were not significant, or they were coincidental (Table 1).

In the 13 male patients with spinal stenosis, 65 and older, according to the localization of the central and subarticular stenotic changes, the most frequently affected levels were L4 (in each patient) and L3 (in 5 patients). Stenotic changes in the foraminal zone were the most frequent finding at L4 level (in 8 patients) and at L3 level (in 5 patients) (Figure 2).

Table 1: **Distribution of different types of spinal stenosis in old adult males and females.**

Patients, 65 and older	Number of patients with central and subarticular stenosis	Number of patients with foraminal stenosis	Total number of patients with spinal stenosis
Males	13	8	13
Females	14	10	14
Total	27	18	27

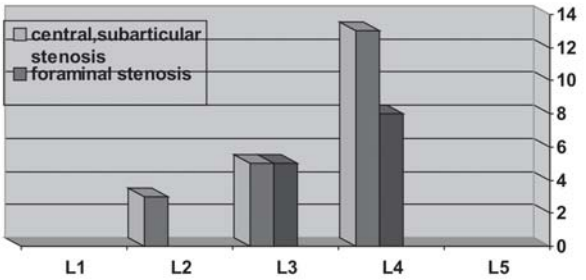

Figure 2: Segmental distribution of different types of spinal stenosis in males 65 and older.

Of the 13 male patients with spinal stenosis, 7 had cross-sectional area of the canal < 100 mm^2 at one level, 3 patients at two levels and 3 at three levels. Severe stenotic changes with the cross-sectional area of the canal < 70 mm^2 were found in 3 old male patients. One level spinal stenosis was the most frequent finding in male patients (Figure 3).

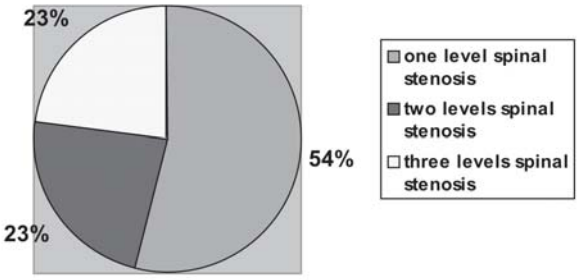

Figure 3: Percentage of male patients with one and multi-level spinal stenosis.

Of the 13 female patients with spinal stenosis, 65 and older, according to the localization of the central and subarticular stenotic changes, the most frequently affected levels were L4 level (in each patient), L3 level (in 13 patients) and L2 level (in 7 patients). Stenotic changes in the foraminal zone were the most frequent finding at L4 (in 10 patients), L3 (in 8 patients) and L2 level (in 7 patients) (Figure 4).

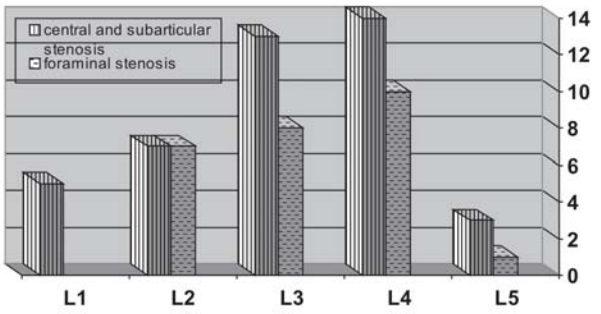

Figure 4: Segmental distribution of different types of spinal stenosis in old female adults (65 and over).

Of the 14 female patients with spinal stenosis, 8 had cross-sectional area of the canal < 100 mm^2 at two and three levels. Severe spinal stenosis with cross-sectional area of the canal < 70 mm^2 was found in 10 old female patients. In 5 patients almost the entire lumbar segment of the vertebral column was stenotic. Two and three levels spinal stenosis were the most frequent finding in the old female patients (Figure 5).

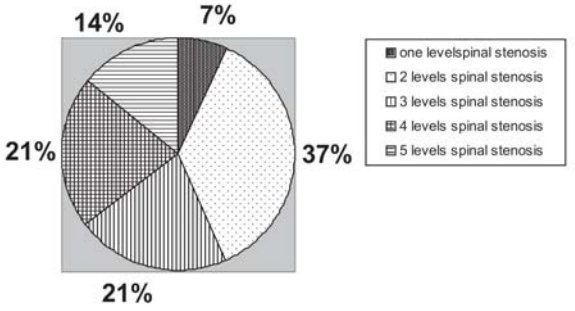

Figure 5: Percentage of female patients with one and multi-level spinal stenosis.

One level spinal stenosis was significantly more frequent finding in male patients (p=0.0131).

There was a significant difference in the segmental distribution of the spinal stenotic changes between old adult male and female patients (Mann-Whitney U test, Z=-2.644, p=0.0081).

Discussion

MR scans in all symptomatic male and female old adults in our study showed expressed stenotic changes that involved one or more levels of the lumbar spine. Radiologic findings of lumbar spinal stenotic changes are not always conjoined with adequate clinical symptomatology. Many patients whose MR images show severe spinal degenerative stenotic changes are symptom free. Poor correlation between radiological stenosis and symptoms has been reported (6). Clinical symptomatology, physical examination of the patient along with the anatomic demonstration of stenosis on MRI (Magnetic Resonance Imaging) or CT (Computerized Tomography) establish the diagnosis. Lumbar spinal canal is stenotic if it causes compression of its contents, particulary neural and vascular structures.

The limitation of our study is that it included only 27 patients with symptoms of intractable neurogenic claudication. MR images in old female adults showed more expressed stenotic changes that involved almost the entire lumbar spine. Many published studies showed that gender differences should be considered when functional status is assessed and that women had worse functional status than men prior to operative treatment for spinal stenosis. In an investigation for health-related quality of life before and one year after surgery for lumbar spinal stenosis, women had lower pre- and post-operative scores than men (7). Gender differences were found to influence the satisfaction rate after lumbar spine stenosis surgery. The authors concluded that the reasons for this were not related to the surgery and were multifactorial (8). The number of spinal levels operated on is considered to be a predictor of outcomes after surgery (9). In our study, the stenotic process characterized with a tendency to involve several levels including the proximal segments of the lumbar spine was common finding in the old adult females, while in the old adult males the process was mostly confined to one level. Spinal stenosis is a global and multilevel disorder, so the decompression should include all the levels where the compressive syndrom is evaluated with the preoperative imaging study,although the symptomatology may be clinical suggestive of single level unilateral nerve root compression. In another studies women had a 15% higher risk of undergoing further surgery for lumbar spinal stenosis (10).

Retrospondylolisthesis is a condition often conjoined with foraminal stenosis. In our study, spondylolisthesis was conjoined with lumbar spinal stenosis mostly in old adult females. In this case the posteroinferior margin of the upper vertebra is moving posteriorly to the foramen while the superior articular process of the lower vertebra is moving anteriorly in the foramen. Asymmetric anterior slipping of the vertebral body (rotatory subluxation) can provoke significant narrowing in the zone of lateral recesses and in the foraminal zone. Stenotic changes in older adults are a result of combination of many factors.

Surgery is generally an accepted treatment of spinal stenosis when conservative treatment has failed. Modern trends are recommending limited or less invasive operative decompression with preserving the elements of stabilization and anatomical structures to decrease a risk of postoperative instability. Spinal surgery is the only way to change the anatomy of the spine and give the nerves more room. Patients who underwent surgery showed significantly more improvement in all primary outcomes than did patients who were treated nonsurgically (11,12). Some authors reported a greater improvement in patient-recorded outcomes for surgery compared to nonsurgical treatment at one and four year follow-ups (13,14). Many studies reported the long-term results of spinal surgery, over a 5-year period and they tend to deteriorate with time (15). Deterioration is due to the progressive nature of osteoarthritis, senile osteoporosis and to the overall aging process. Posmenopausal women have insufficient estrogen levels (estrogen helps to maintain sufficient calcium in the skeletal system). Women are prone to osteoporosis because their bones are smaller and contain less mass than man's bones.

In conclusion we can say that, before making a decision to perform an adequate treatment of degenerative spinal stenosis, it should be taken into consideration that gender differences are also an important factor to asses the risk in each optional treatment versus the expected benefit. MR images in old female adults showed more expressed stenotic changes that involved almost the entire lumbar spine, including the proximal segments. Risk factors that are behind the less favourable postsurgical outcomes score in women should be further investigated. Degenerative lumbar stenosis should be treated with an appropriate procedure that treats this condition completely, not partially. Correct planning of an adequate technique for operative decompression in older adults, particulary females should preserve much of the anatomy and biomechanical function of the lumbar spine.

References

1. Postacchini F. Management of lumbar spinal stenosis. J Bone Joint Surg Br. 1996;78(1):154-164. PMID:8898152

2. Wong HK, Bose K. Spinal stenosis-Result of surgical treatment. J West Pac Orthop Assoc.1992;29:37-41.

3. Katz JN, Lipson SL, Brick GW et al. Clinical correlates of patients satisfaction after laminectomy for degenerative lumbar spinal stenosis. Spine (Phila Pa 1976). 1995; 20(10):1155-1160. doi:10.1097/00007632-199505150-00008 PMID:7638658

4. Amundsen T, Weber H, Nordal HJ et al. Lumbar spinal stenosis: conservative or surgical management? A prospective 10-year study. Spine. 2000; 25:1424-1436. doi:10.1097/00007632-200006010-00016 PMID:10828926

5. Yukawa Y, Lenke LG, Tenhula J et al. A comprehensive study of patients with surgically treated lumbar spinal stenosis with neurogenic claudication. J Bone Jont Surg. [Am] 2002;84:1954-9. PMID:12429755

6. Herno A, Airaksinen O, Saari T. Computed tomography after laminectomy for lumbar spinal stenosis. Spine. 1994; 19:1975-1978. doi:10.1097/00007632-199409000-00019 PMID:7997932

7. Jannson KA, Nemeth G,Granath F, Jonsson B, Blomqvist P. Health-related quality of life (EQ-5D) before and one year after surgery for lumbar spinal stenosis. J Bone Joint Surg. [Br] 2009;91-B:210-16. doi:10.1302/0301-620X.91B2.21119 PMID:19190056

8. Shabat S, Folman Y, Arinzon Z, Adunsky A, Catz A, Gepstein R. Gender differences as an influence on patient's satisfaction rates in spinal surgery of elderly patients. Eur Spine J. 2005;14:1027-1032. doi:10.1007/s00586-004-0808-z PMID:15912353

9. Gunzberg R, Keller T, Szpalski M, Vandeputte K, Spratt KF. Clinical and psychofunctional measures of conservative decompression surgery for lumbar spinal stenosis: a prospective cohort study. Eur Spine J. 2003;12(2):197-204. PMID:12709858

10. Jannson KA, Nemeth G,Granath F, Blomqvist P. Spinal stenosis re-operation rate in Sweden is 11% at ten years: a national analysis of 9664 operations. Eur Spine J. 2005;7:659-63. doi:10.1007/s00586-004-0851-9 PMID:15754213

11. Weinstein JN,Tosteson TD,Lurie JD,Tosteson AN,Blood E,Hanscom B et al. Surgical versus nonsurgical therapy for lumbar spinal stenosis. N Engl J Med. 2008;358(8):818-25. doi:10.1056/NEJMoa0707136 PMID:18287602 PMCID:2576513

12. Murphy RD, Hurwitz LE,Gregory AA, Clary R. A Nonsurgical Approach to the Management of the lumbar spinal stenosis: A prospective observational cohort study. BMC Musculoskelet Disord. 2006;7:16. doi:10.1186/1471-2474-7-16 PMID:16504078 PMCID:1397818

13. Atlas SJ, Deyo RA, Keller RB et al. The Maine Lumbar Spine Study, Part III. 1-year outcomes of surgical and nonsurgical management of lumbar spinal stenosis. Spine. 1996;25(15):1787-1794. doi:10.1097/00007632-199608010-00012 PMID:8855463

14. Atlas SJ, Keller RB, Robson D et al. Surgical and nonsurgical management of lumbar spinal stenosis: four- year outcomes from the maine lumbar spine study. Spine.2000; 25(5):556-562. doi:10.1097/00007632-200003010-00005 PMID:10749631

15. Katz JN, Lipson SL, Chang LC et al. Seven to 10 years outcome of decompressive surgery for degenerative lumbar spinal stenosis. Spine. 1996;1:92-8. doi:10.1097/00007632-199601010-00022 PMID:9122770